



CASE REPORTS BOOKLET

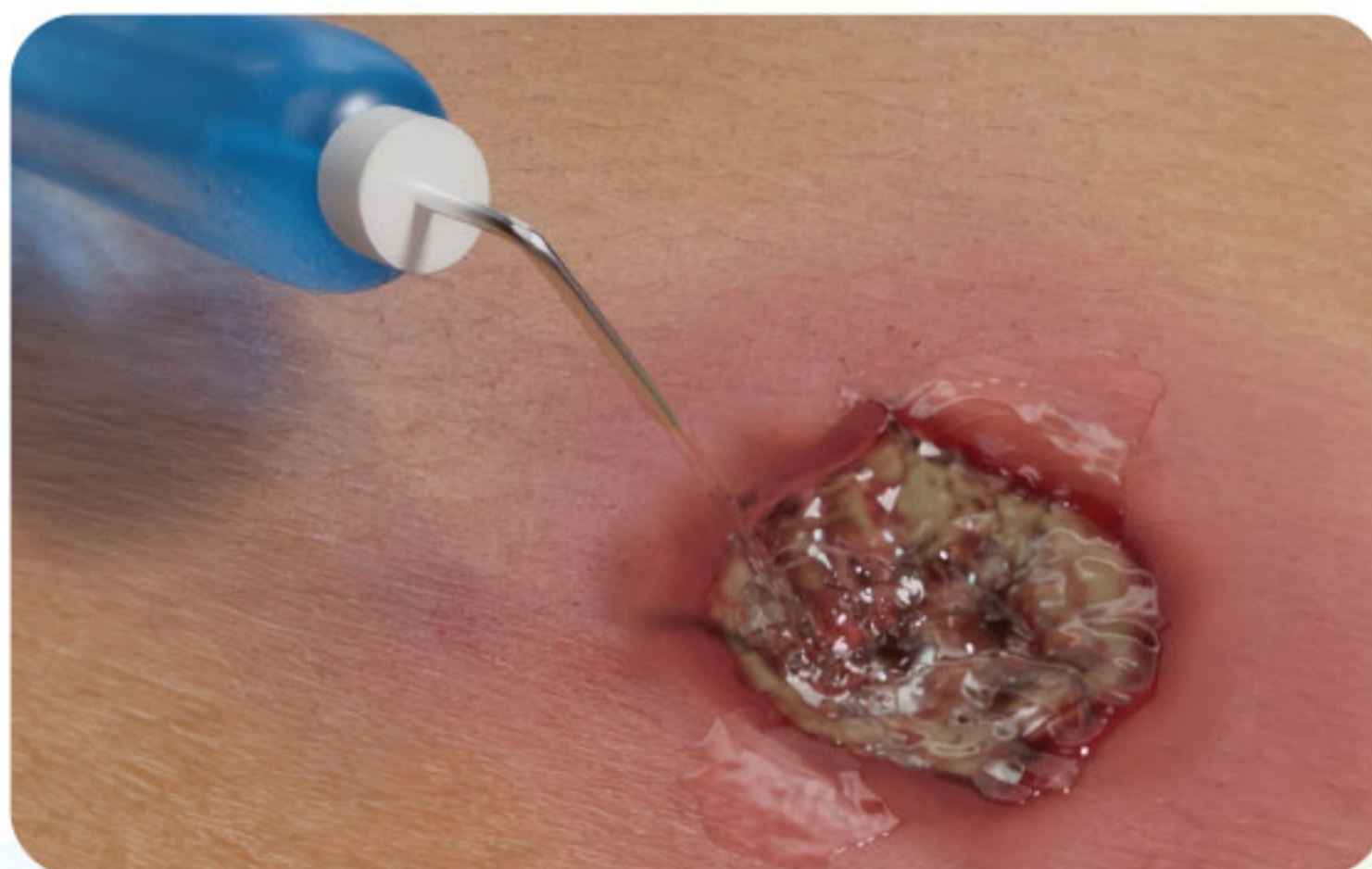DIAGNOSTICS AND THERAPY
FOR CHRONIC WOUNDS

SCAN FOR YOUR
DIGITAL COPY

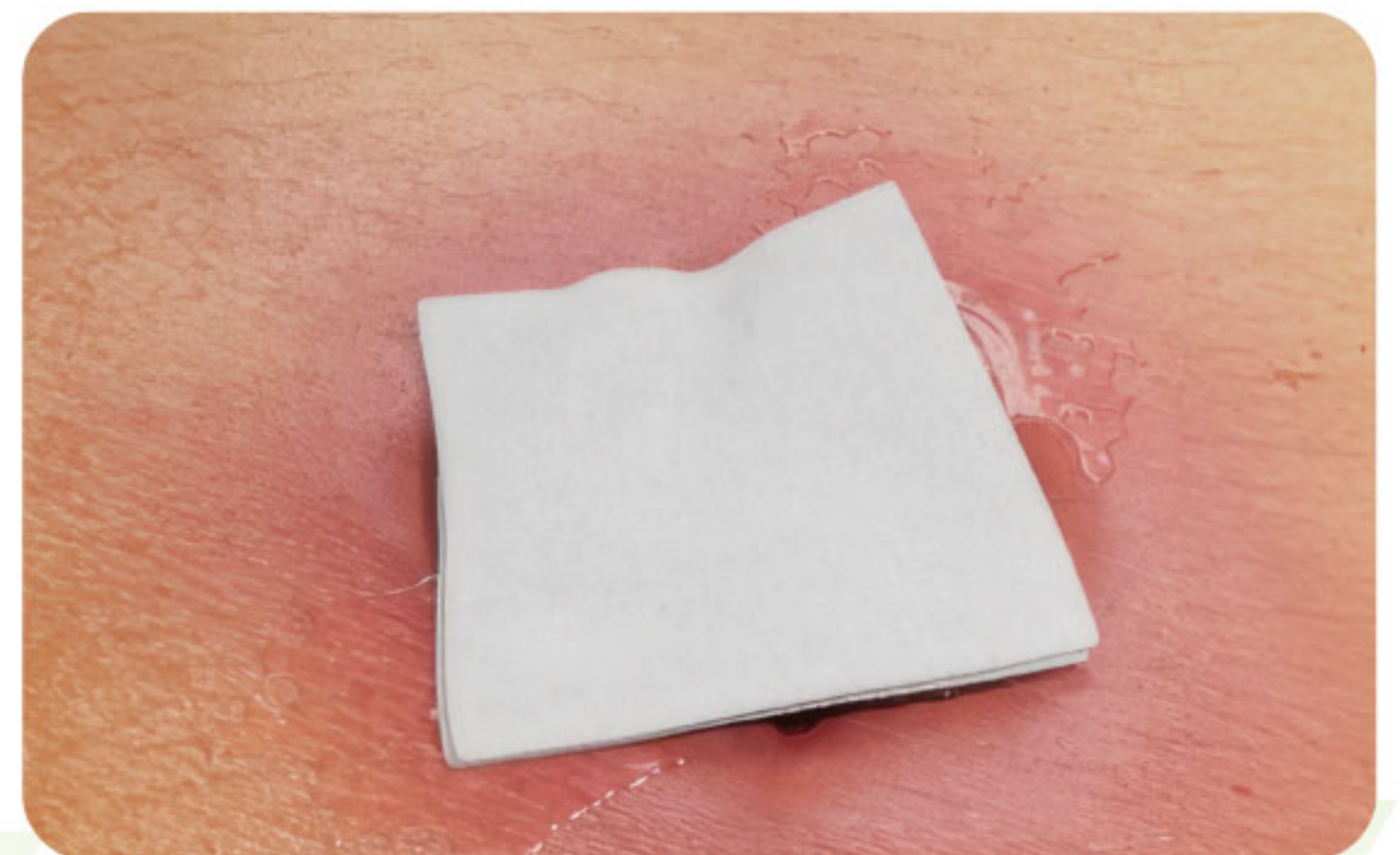



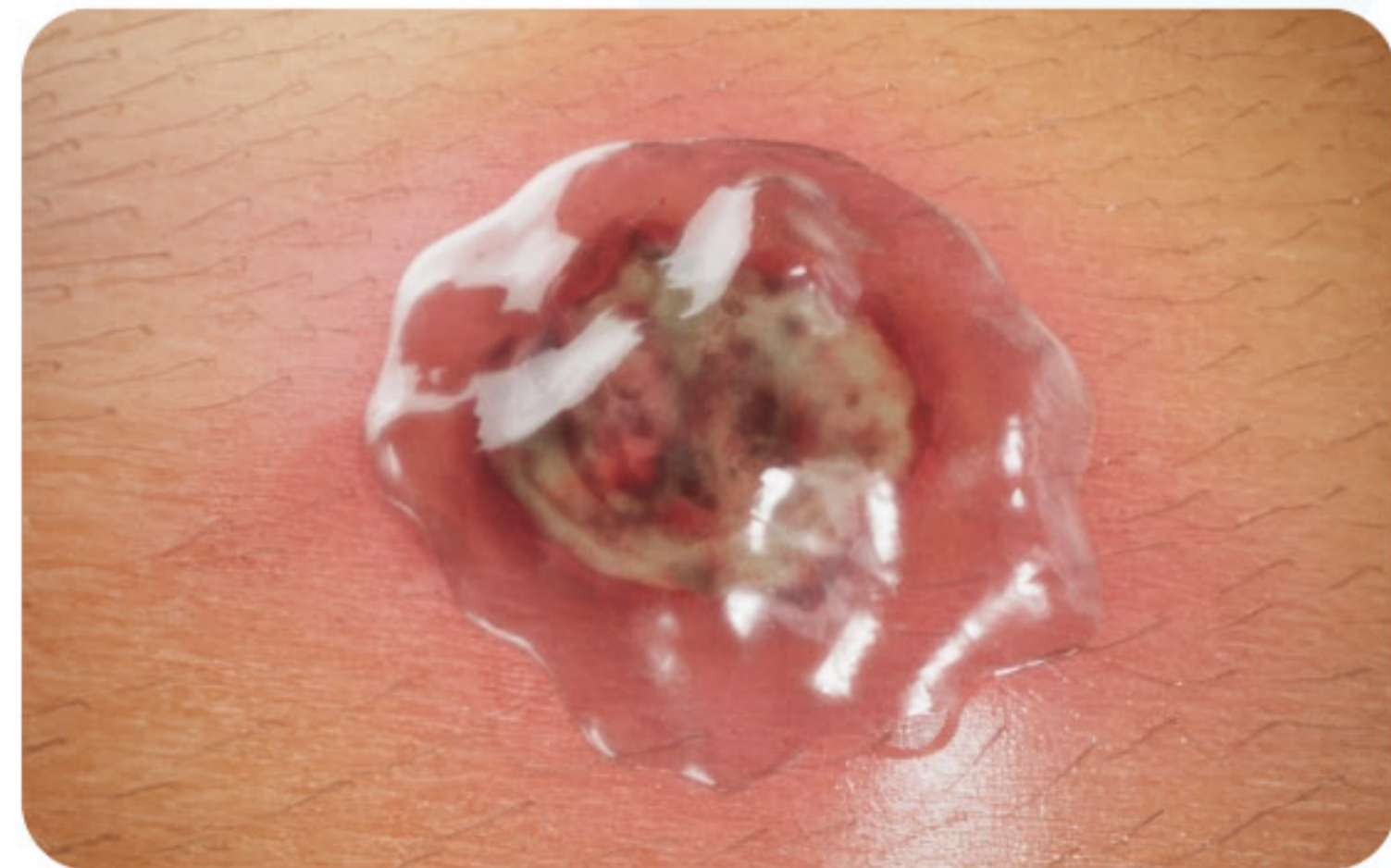
1. Put on gloves and goggles



2. Uncover and cleanse the wound and periwound area



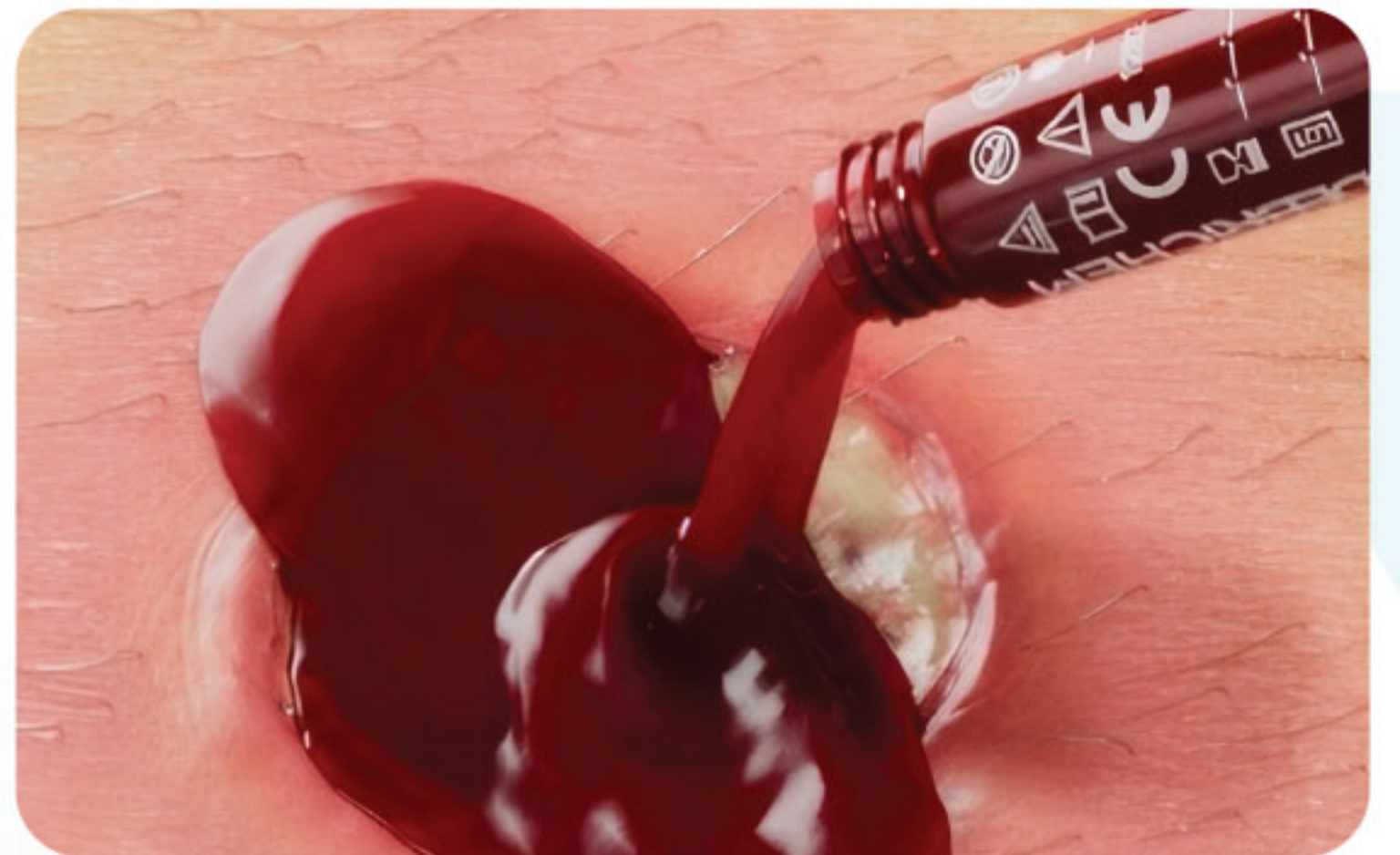3. Dry the wound with dry gauze



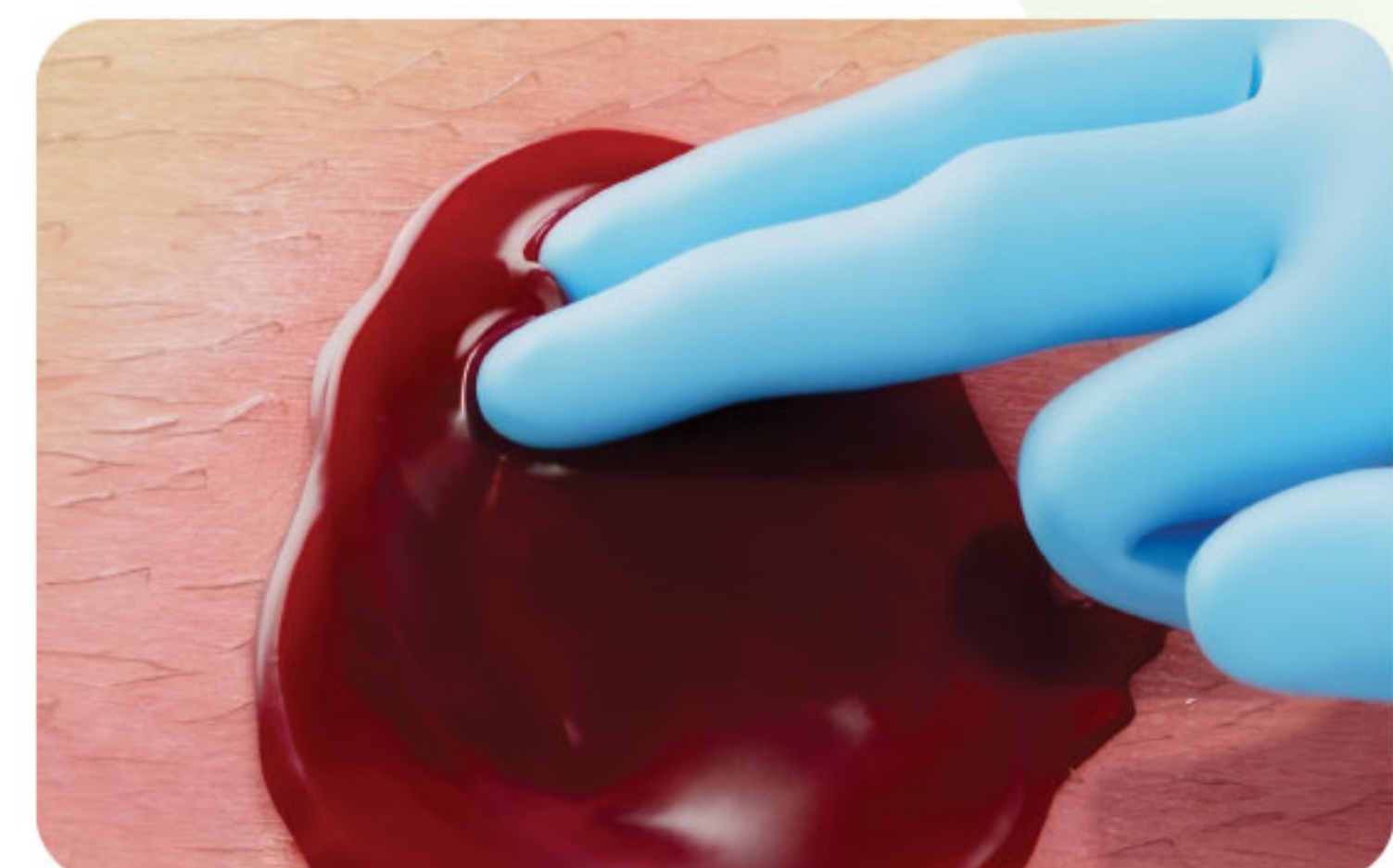4. Apply topical analgesia to wound and periwound (when applicable) and remove after it has taken effect



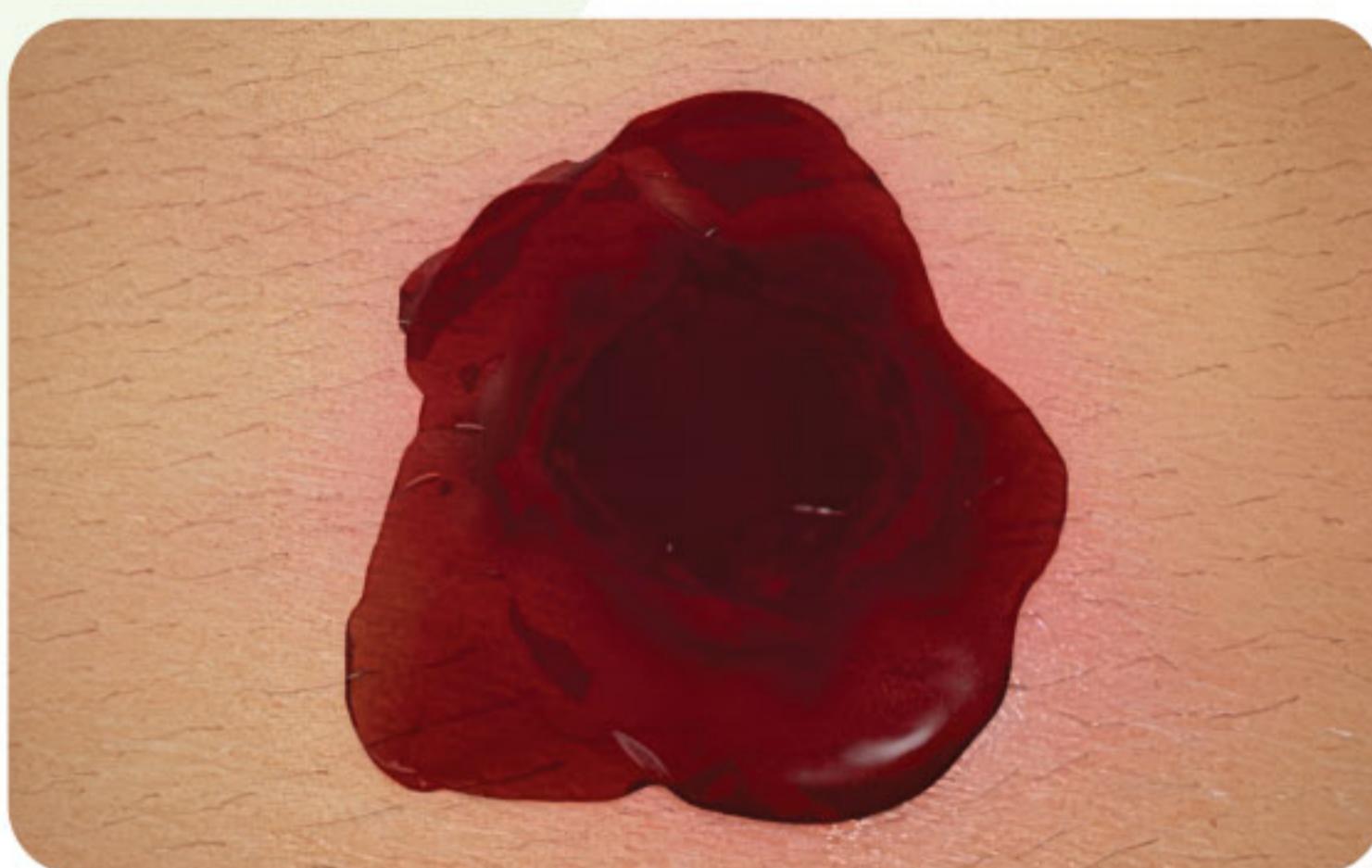
5. Shake the vial vigorously for 30 seconds before opening



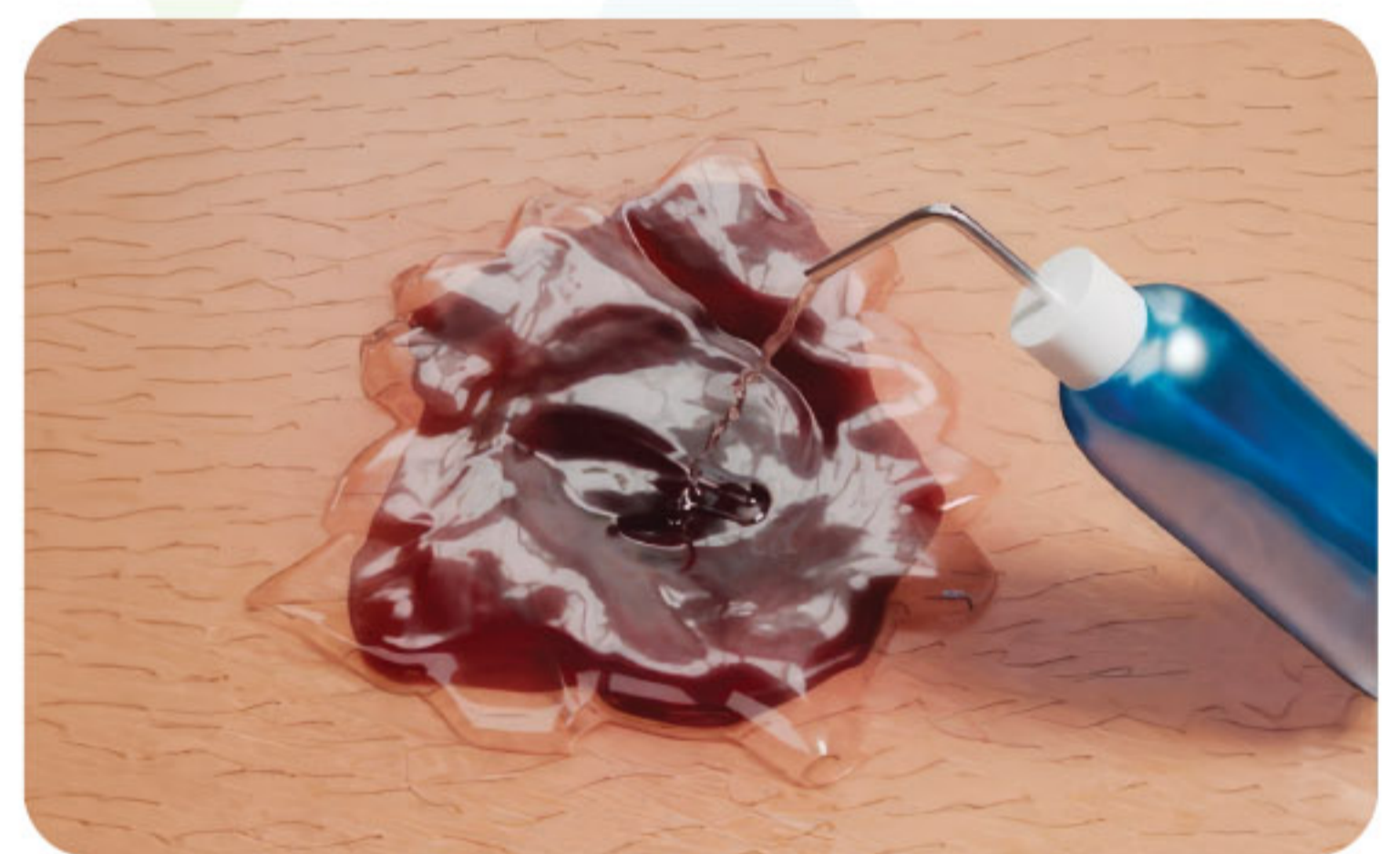
6. Pour DEBRICHEM[®] onto wound, covering 1 cm of periwound skin



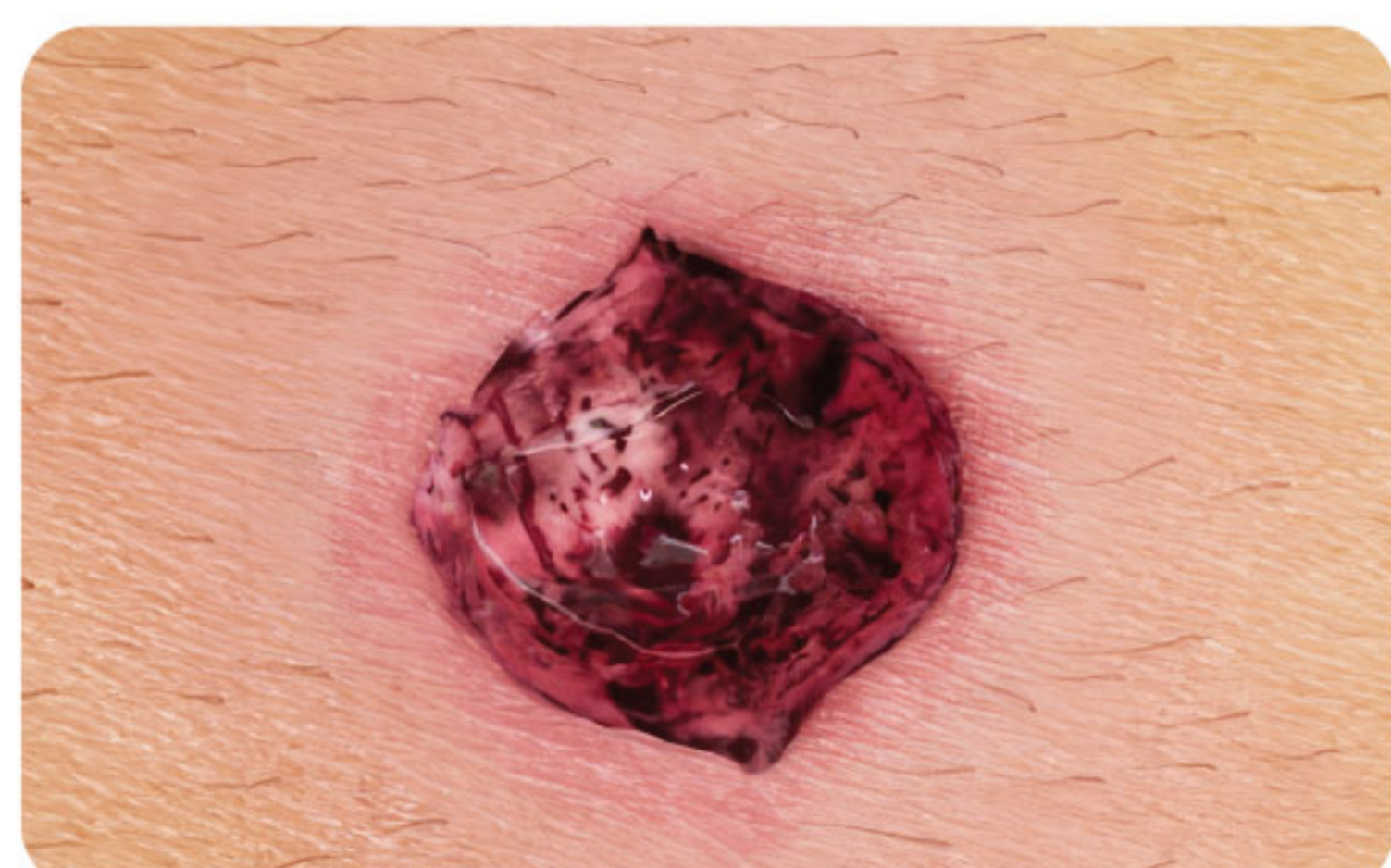7. Spread DEBRICHEM[®] evenly on wound and periwound, applying light pressure with a glove



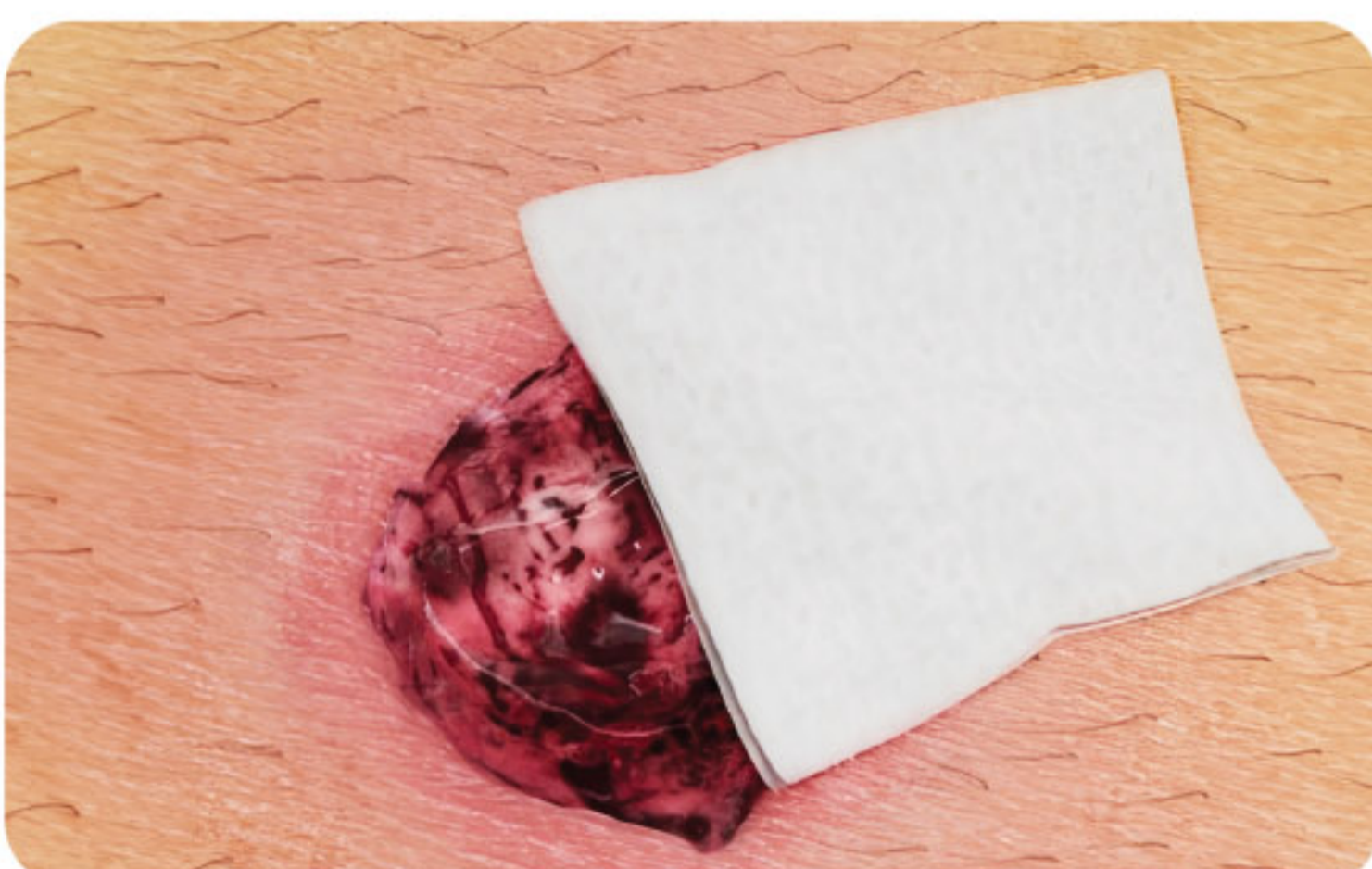8. Leave DEBRICHEM[®] in situ for 60 seconds from first application



9. Rinse the wound with plenty of free-flowing saline or sterile water



10. After application, expect a darker, drier wound



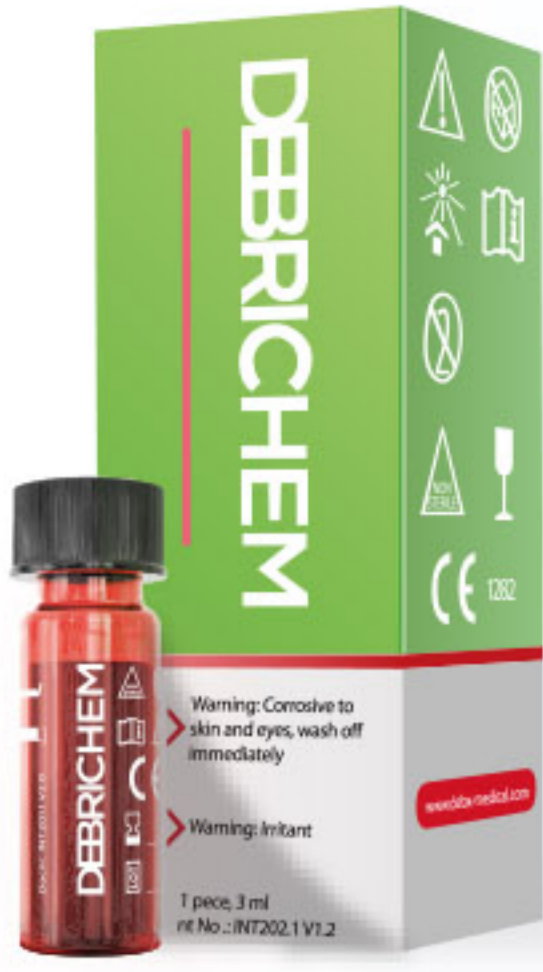11. Remove any remaining loose debris with dry gauze



12. Apply primary and secondary dressings following protocol



SCAN FOR ANIMATED VERSION



CASE 9

75- YEAR-OLD FEMALE WITH
A VENOUS ULCER ON THE LEFT LOWER LEG

AUTHOR

DR. A.COGO, VILLA BERICA, ITALY

ETIOLOGY

VENOUS LEG ULCER



GENERAL MEDICAL HISTORY

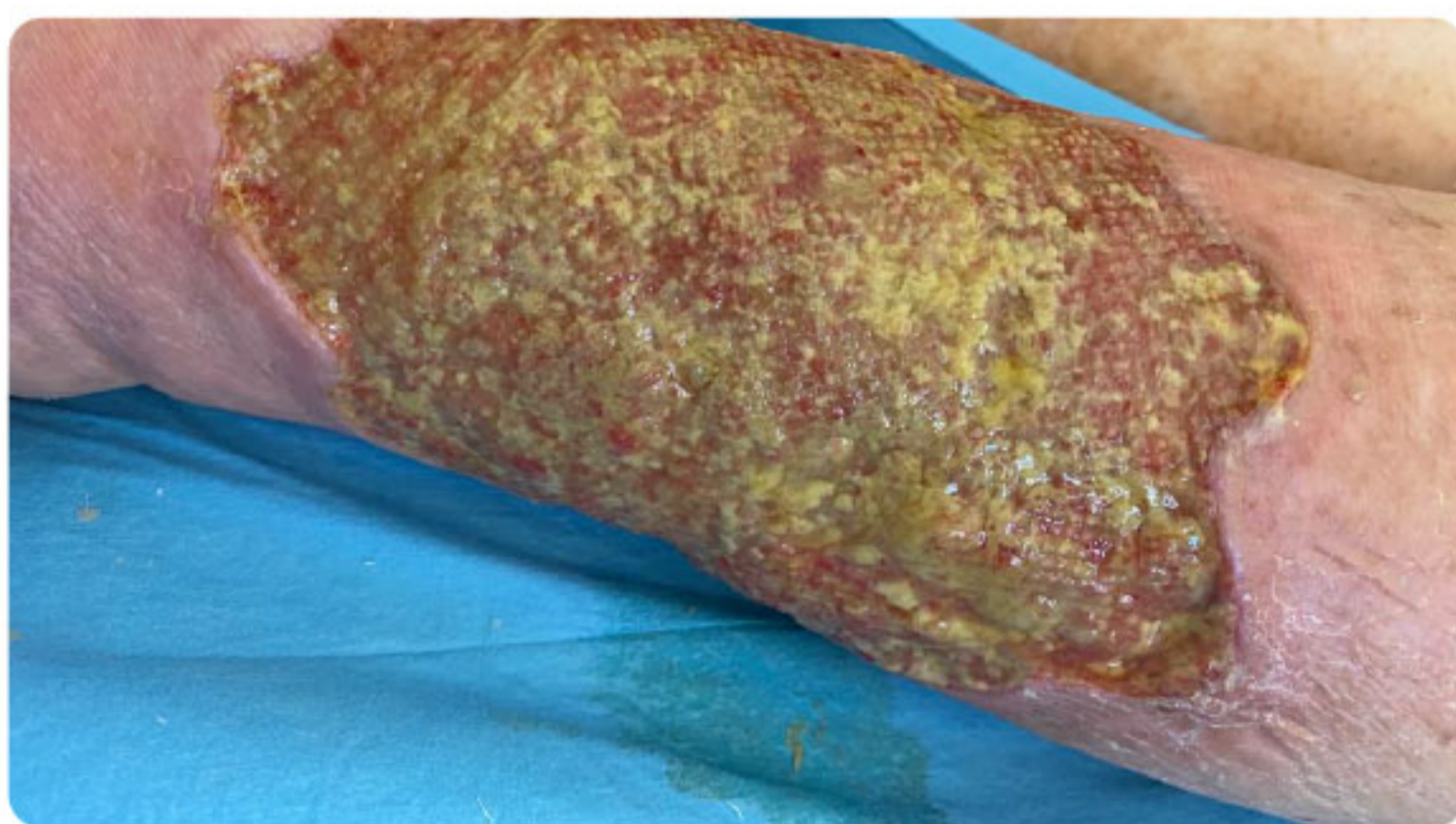
- ✓ Diabetes Mellitus
- ✓ Hypertension

DESCRIPTION

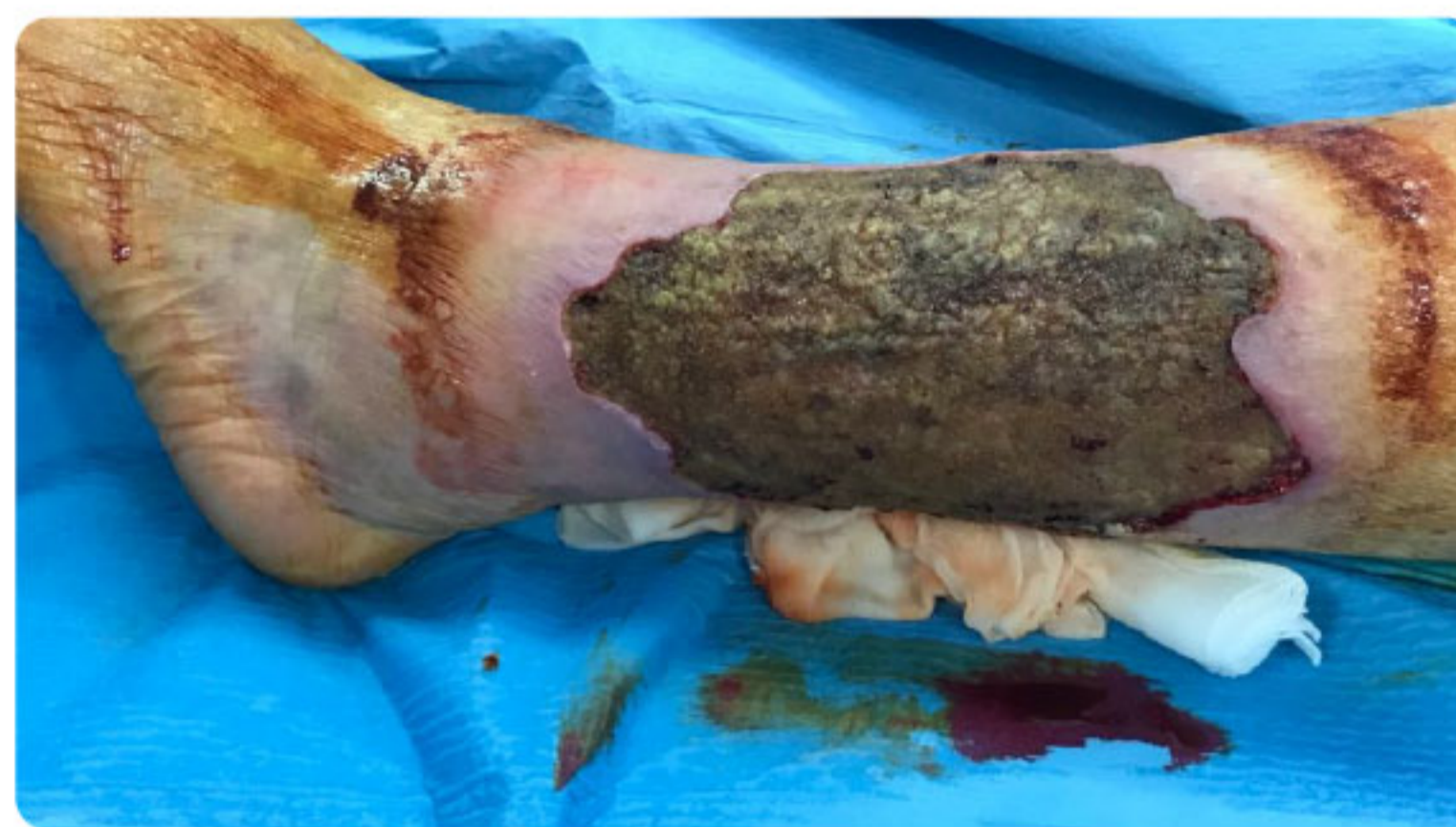The patient visited the clinic with a wound on the lower left leg. This wound has been present for seven months. The patient has diabetes and hypertension that impact wound healing. The wound initially started out as a small trauma lesion. After infection the wound kept on progressing and growing. This increase of the wound occurred despite treatment with advanced dressings and antibiotic therapy, coordinated from home care.

The wound presented at the clinic was heavily exudating (Figure A). the wound bed has tested positive for chronic ulcer pathogens such as pseudomonas aeruginosa. Investigation with echo Doppler excluded any vascular diseases as underlying cause. This diabetic patient received a DEBRICHEM application on the wound bed. Treatment with DEBRICHEM shows a strong carbonisation effect due to the desiccating properties of DEBRICHEM (Figure B). Immediately after debridement using DEBRICHEM negative pressure therapy was initiated (Figure C). This stayed on for three days, however exudation had stopped within the first day after DEBRICHEM application. At day three the wound bed is much less carbonized and granulation is starting (figure D). At day six full granulation was visible, negative pressure therapy was cancelled and the patient was scheduled for a skin graft at day eight.

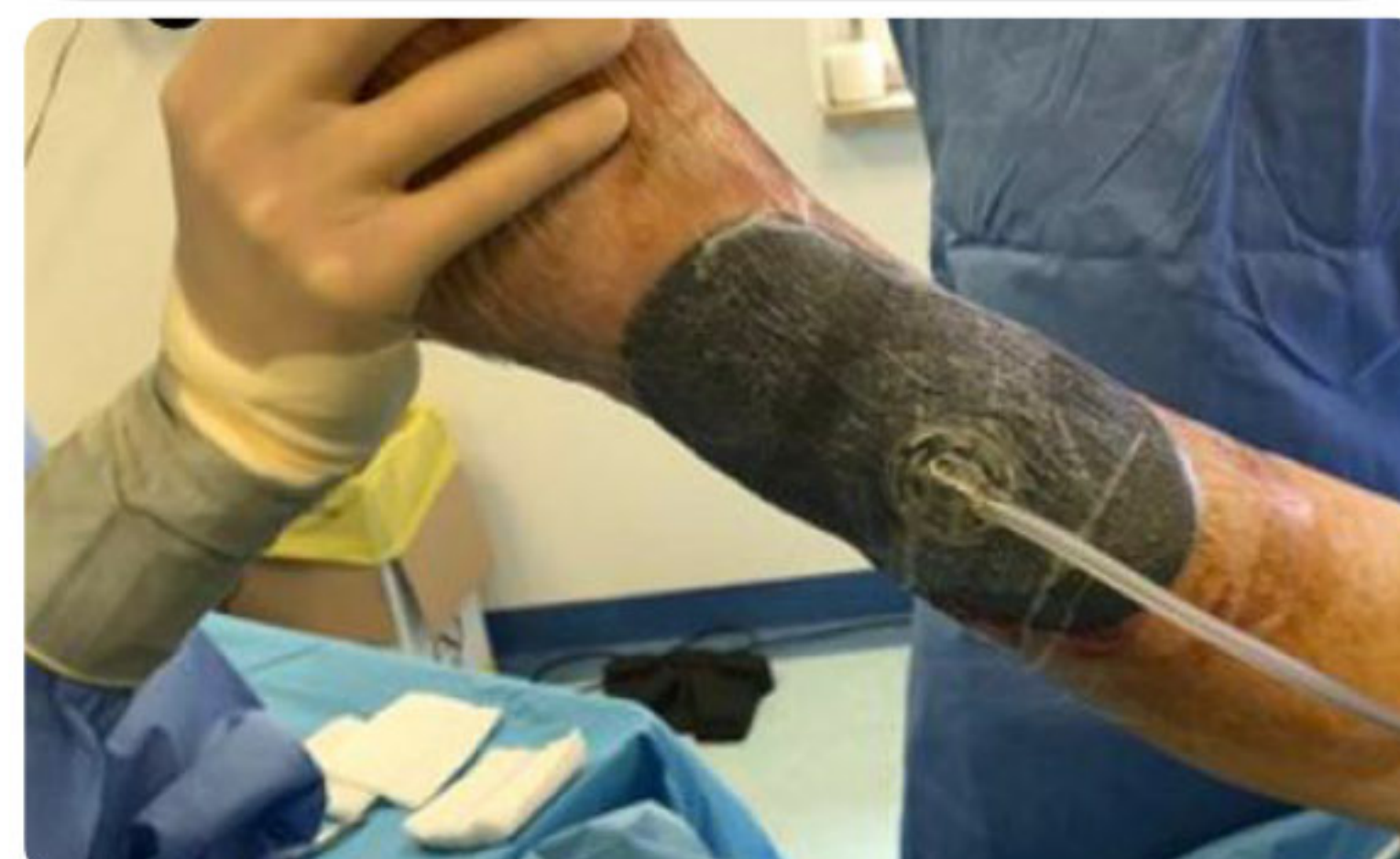PROGRESS



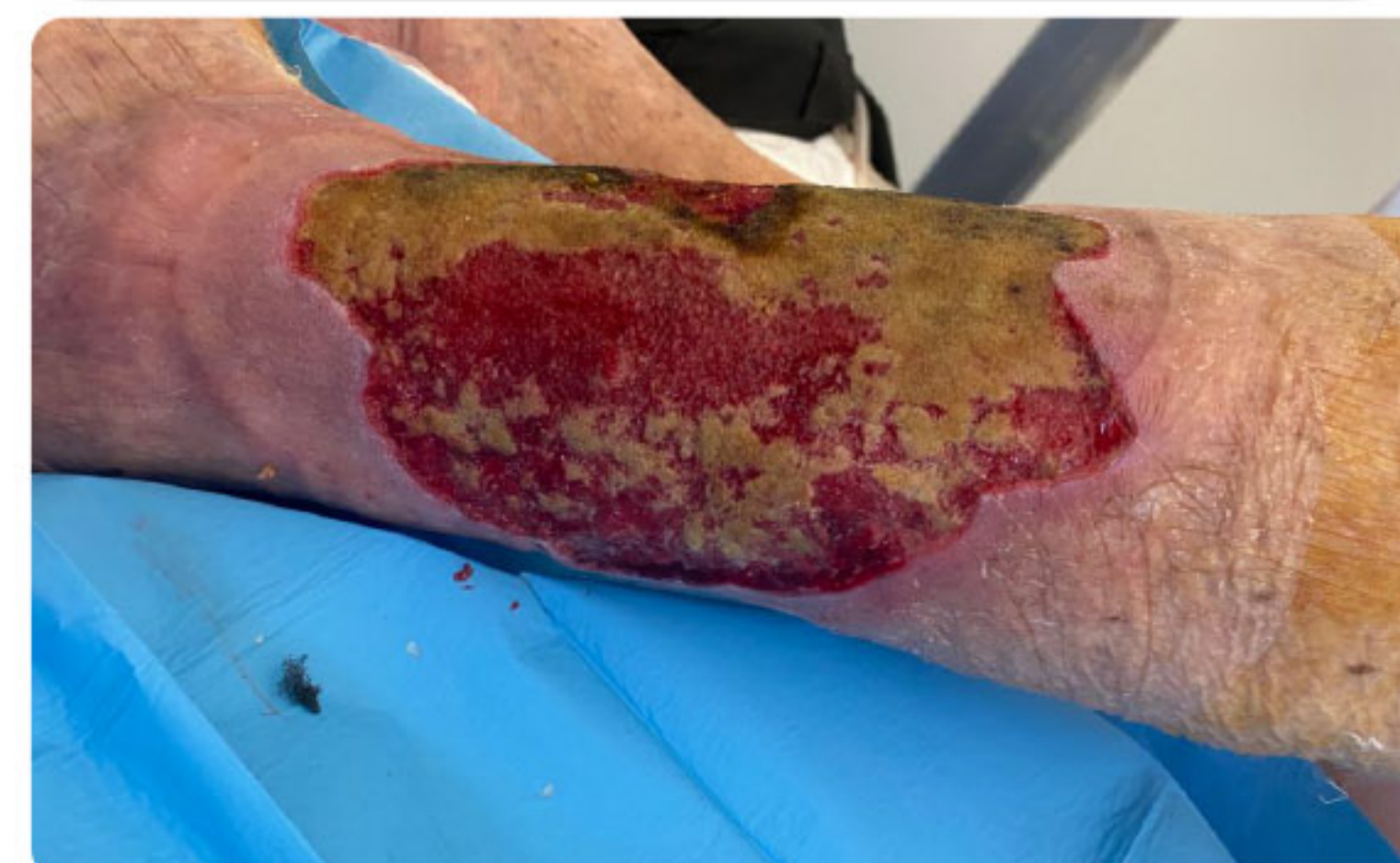1. Figure A: Wound presented before treatment



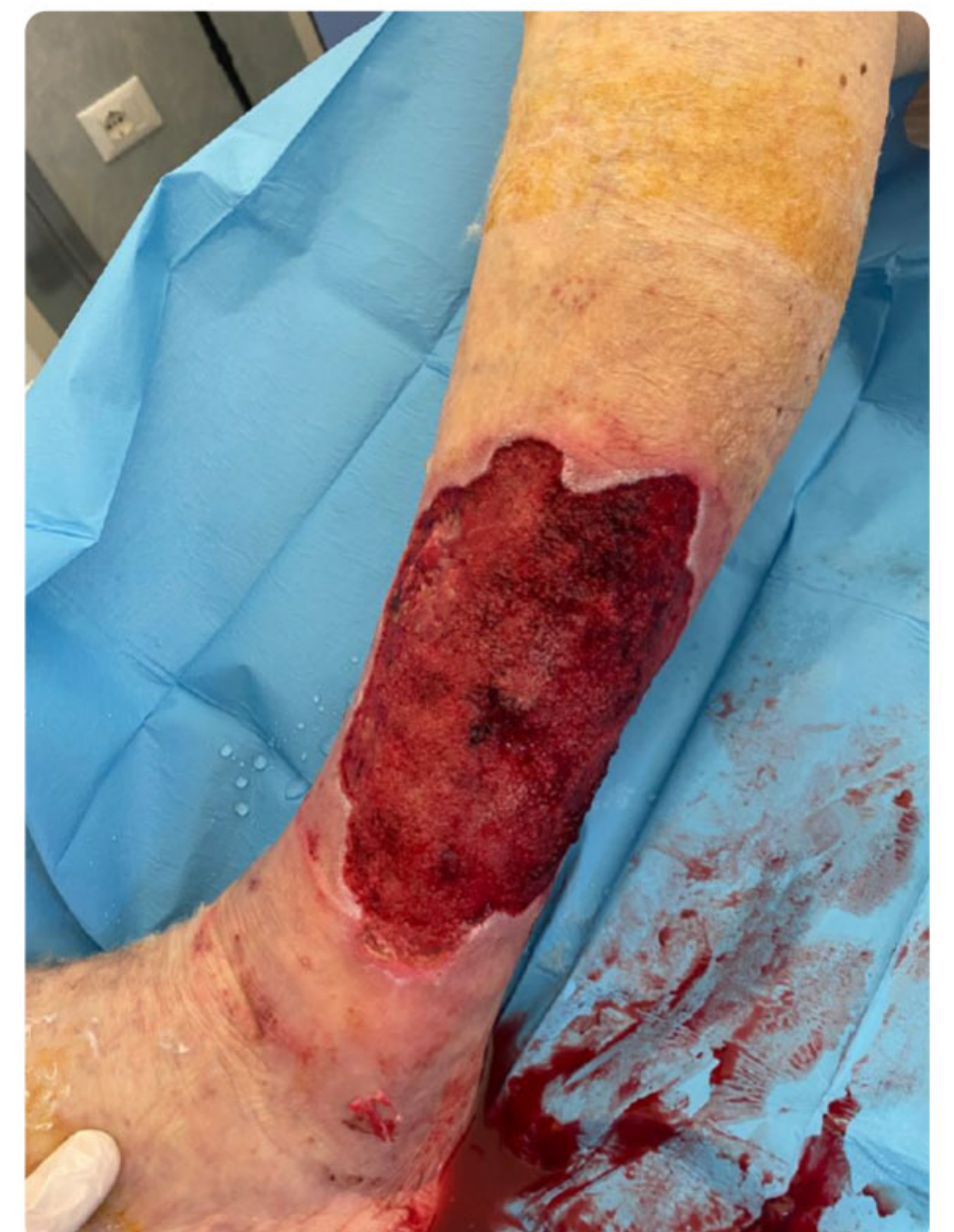2. Figure B: Carbonization of wounded after DEBRICHEM



3. Figure C: Application of NPWT



4. Figure D: 3 days post



5. Figure E: 7 days post DEBRICHEM



CASE 19

77- YEAR-OLD FEMALE WITH
A VENOUS ULCER ON THE LEFT LOWER LEG

AUTHOR

DR. A.COGO, VILLA BERICA, ITALY

ETIOLOGY

VENOUS LEG ULCER



GENERAL MEDICAL HISTORY

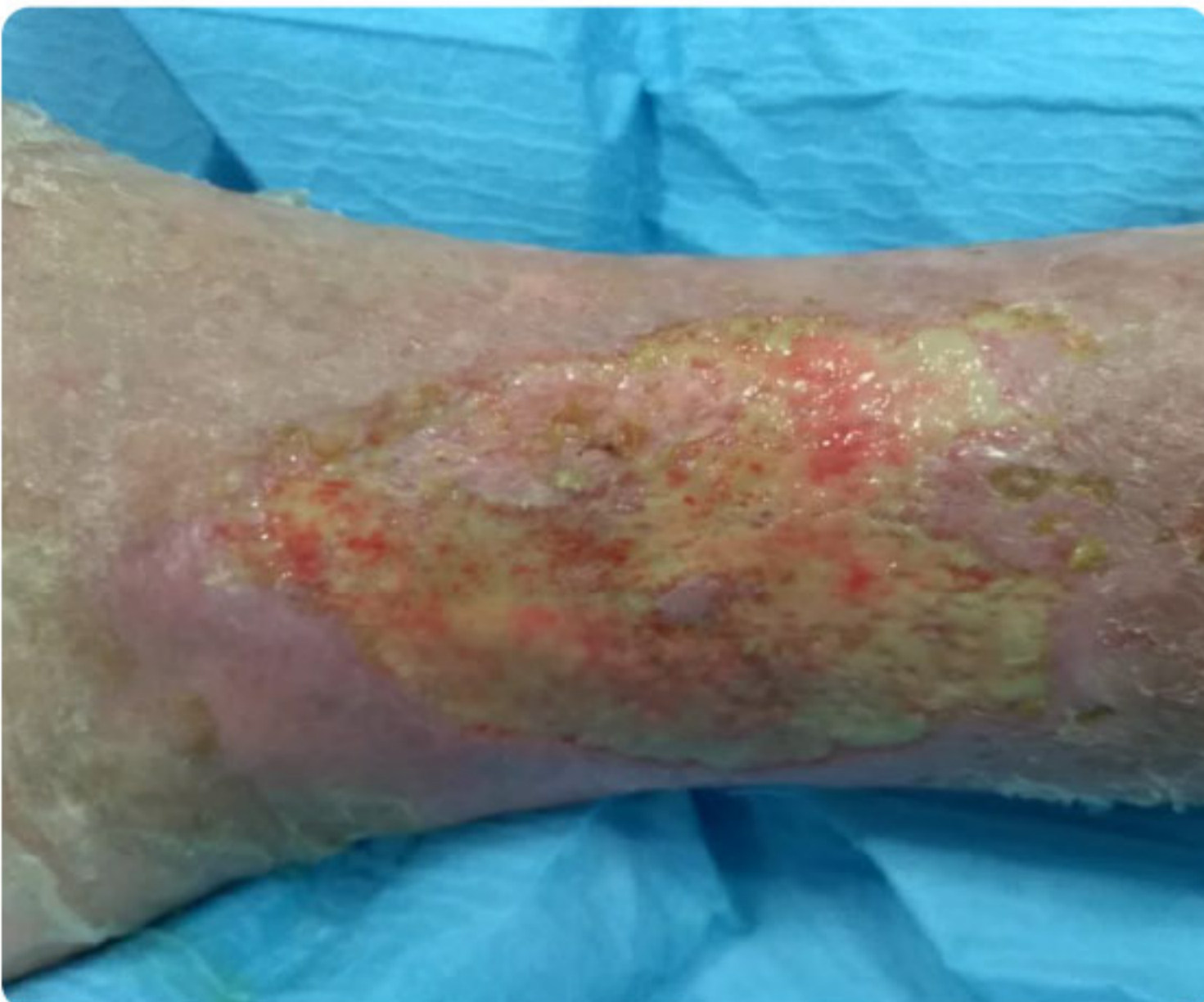- ✓ Diabetes
- ✓ Hypercholesterolemia
- ✓ Hypertension

DESCRIPTION

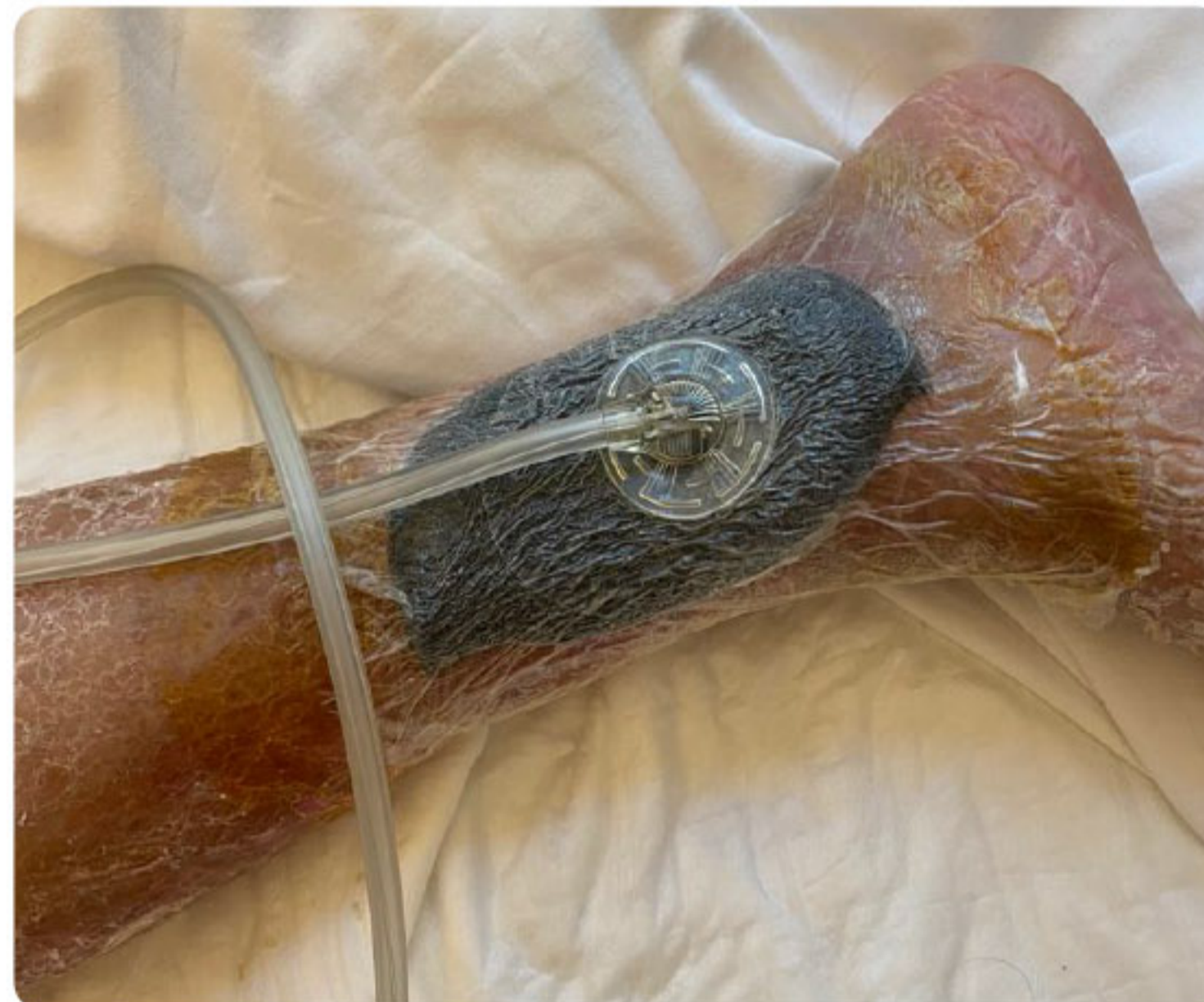
The patient entered the clinic with a lesion on lower left leg. The wound evolved into an ulcer in 4 months with and rapidly became infected (Figure A). Comorbidities are diabetes, Hypercholesterolemia and hypertension. The dressings used in home care to reduce infection did not have any effect prior to DEBRICHEM treatment. The wound shows a moist sloughish layer produced by a pseudomonas infection. The day of presentation the wound was debrided with DEBRICHEM and immediately vacuum therapy was started (Figure B).

The non-vital tissue on the wound bed easily detached with brushing with a dry gauze at 3 days post DEBRICHEM treatment, following a healthy granulating woundbed (Figure C). After 7 days 100% granulation was reached (Figure D). Treatment for post DEBRICHEM and vacuum therapy was set at a biweekly change of Vaseline gauze dressings. After 70 days the wound bed showed complete healing (Figure E).

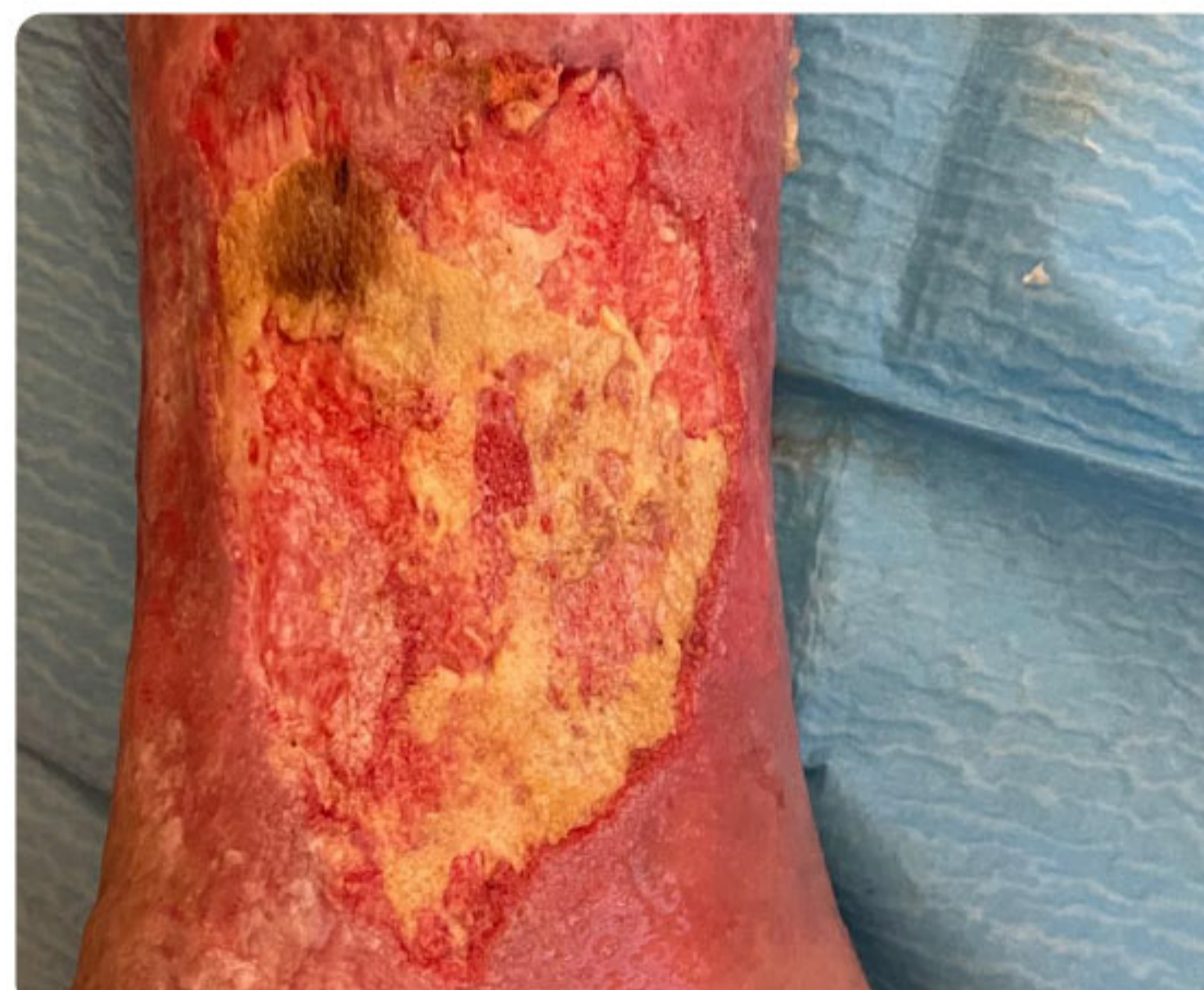PROGRESS



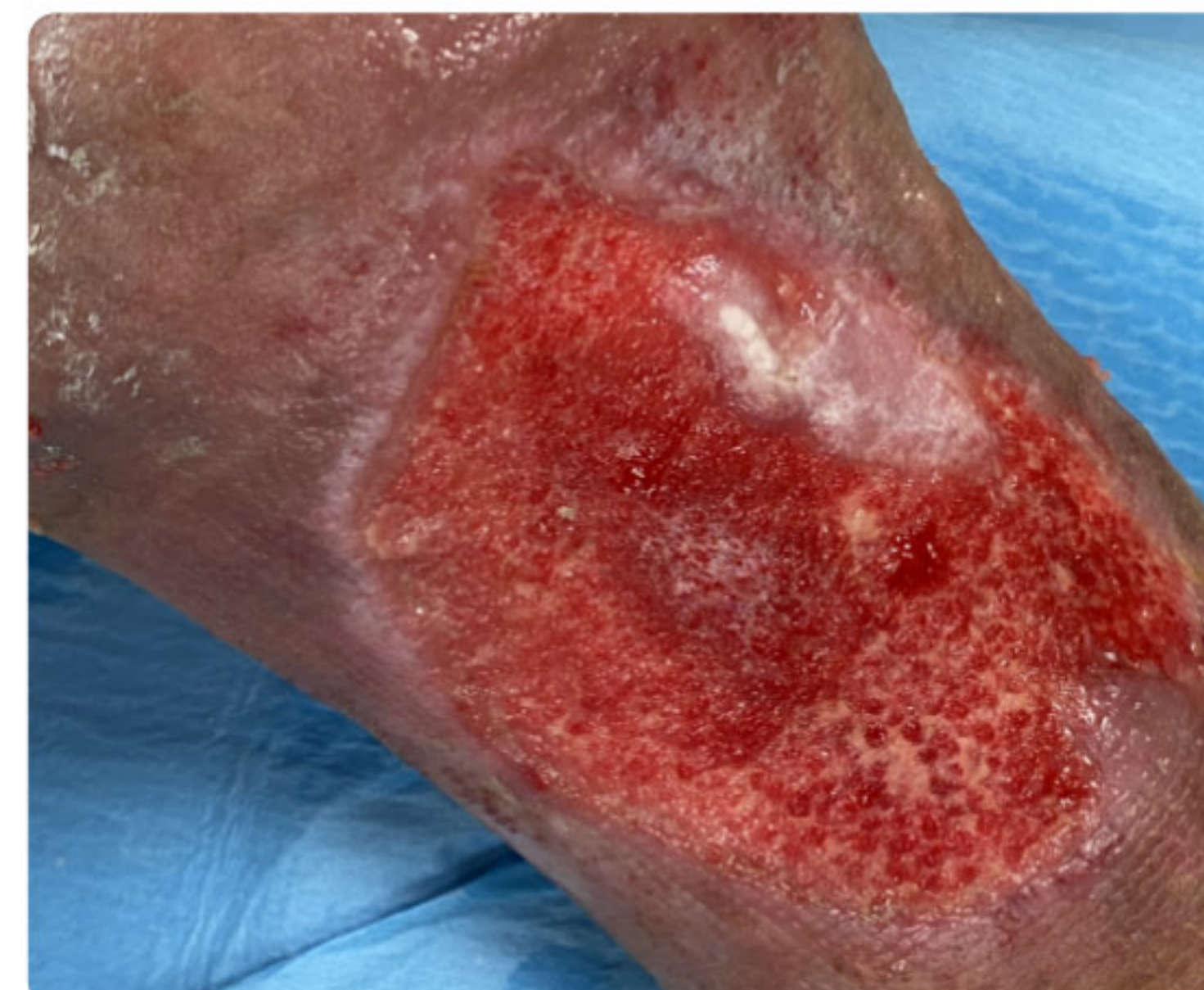A Figure A: Ulcer at presentation



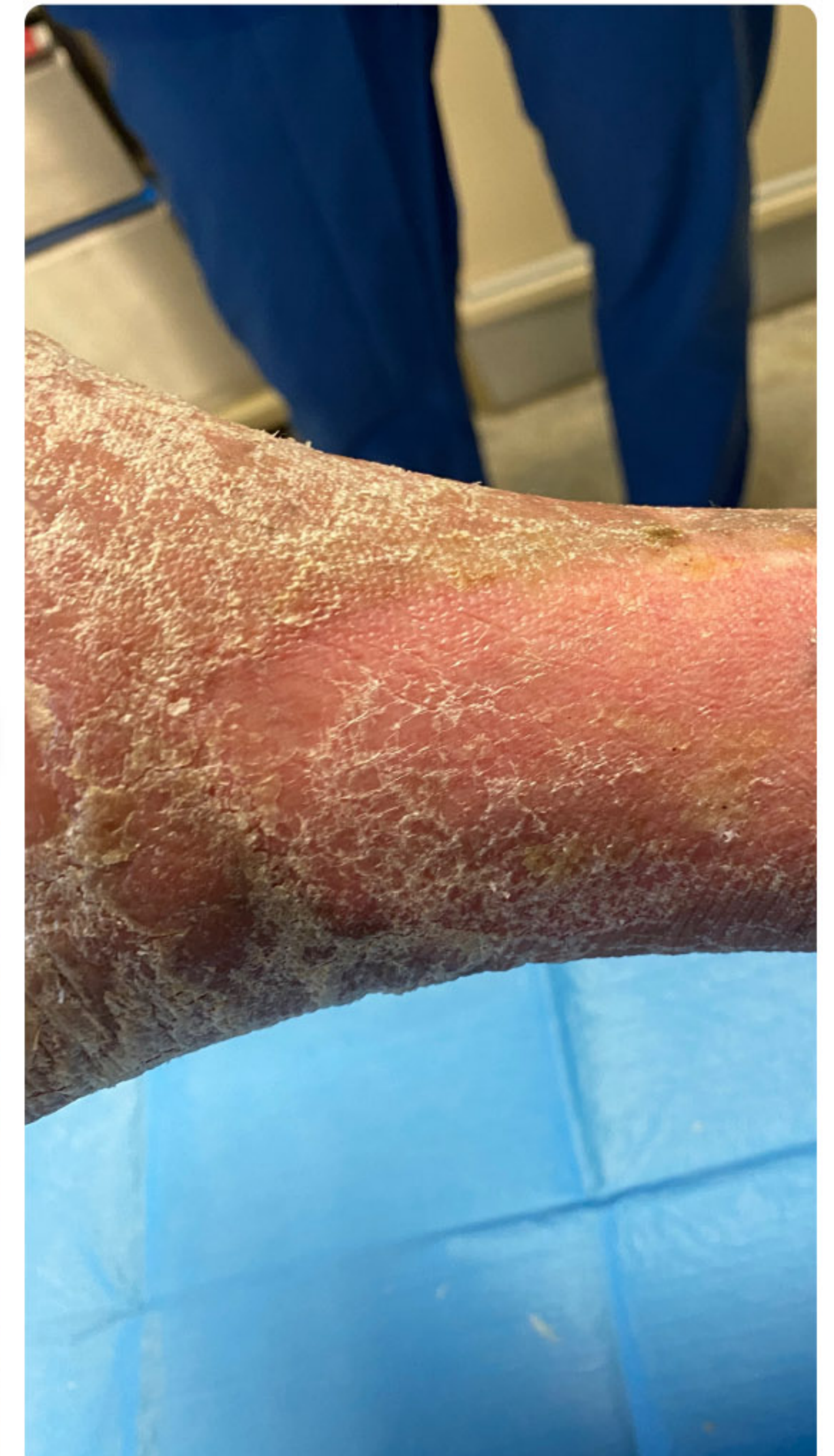B Figure B: After DEBRICHEM treatment in vacuum treatment



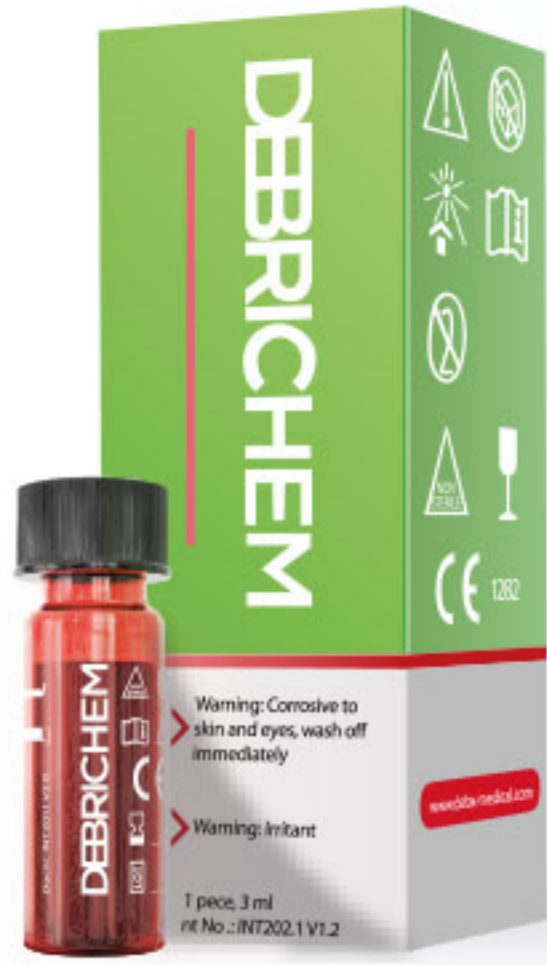C Figure C: 3 days post DEBRICHEM treatment



D Figure D: 7 days post DEBRICHEM treatment



E Figure E: 70 days after DEBRICHEM treatment



CASE 39

94- YEAR-OLD FEMALE WITH A
VENOUS ULCER ON THE LEFT LOWER LEG

AUTHOR

R. MACHADO, CENTRO HOSPITALAR
DO PORTO, PORTUGAL

ETIOLOGY

VENOUS LEG ULCER



GENERAL MEDICAL HISTORY

✔ Type 6 venous insufficiency



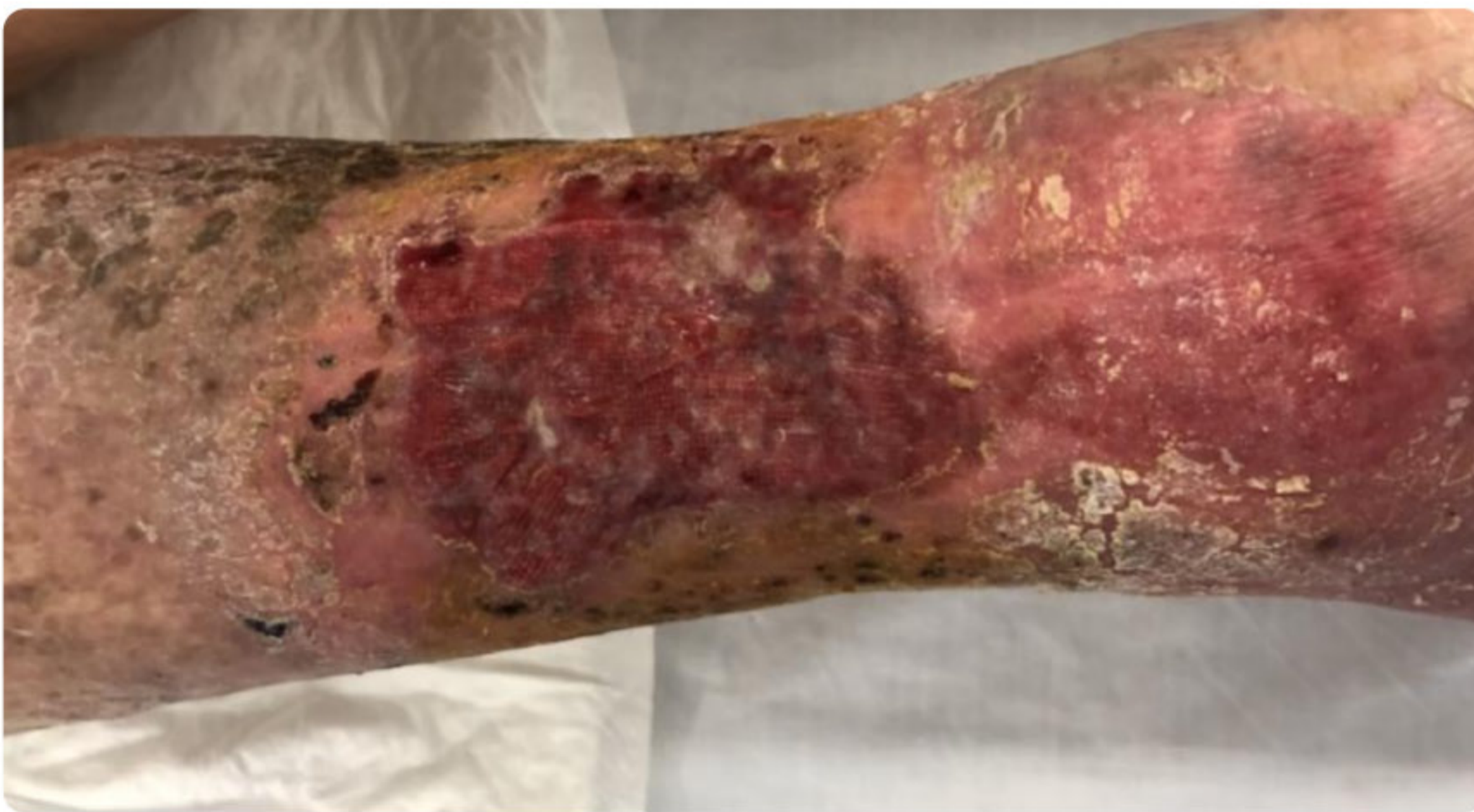DESCRIPTION

A 94-year-old female non-smoker with Type 6 chronic venous insufficiency presented with a non-healing wound persisting for 4 years (Figure A). During DEBRICHEM treatment the patient experienced significant pain. The procedure took place in the operating room under local anaesthesia (Figure B), coinciding as the clinician was testing another device for a different purpose. Following DEBRICHEM application an iodine and bandage were utilized.

Notable improvement in wound observed 3 weeks post-DEBRICHEM application. The wound noted to be low exudative and dehydrated (figure C). Complete wound closure of the wound achieved after 6 weeks of DEBRICHEM application, in conjunction with continued use of Suprasorb X and PHMB (Figure D).

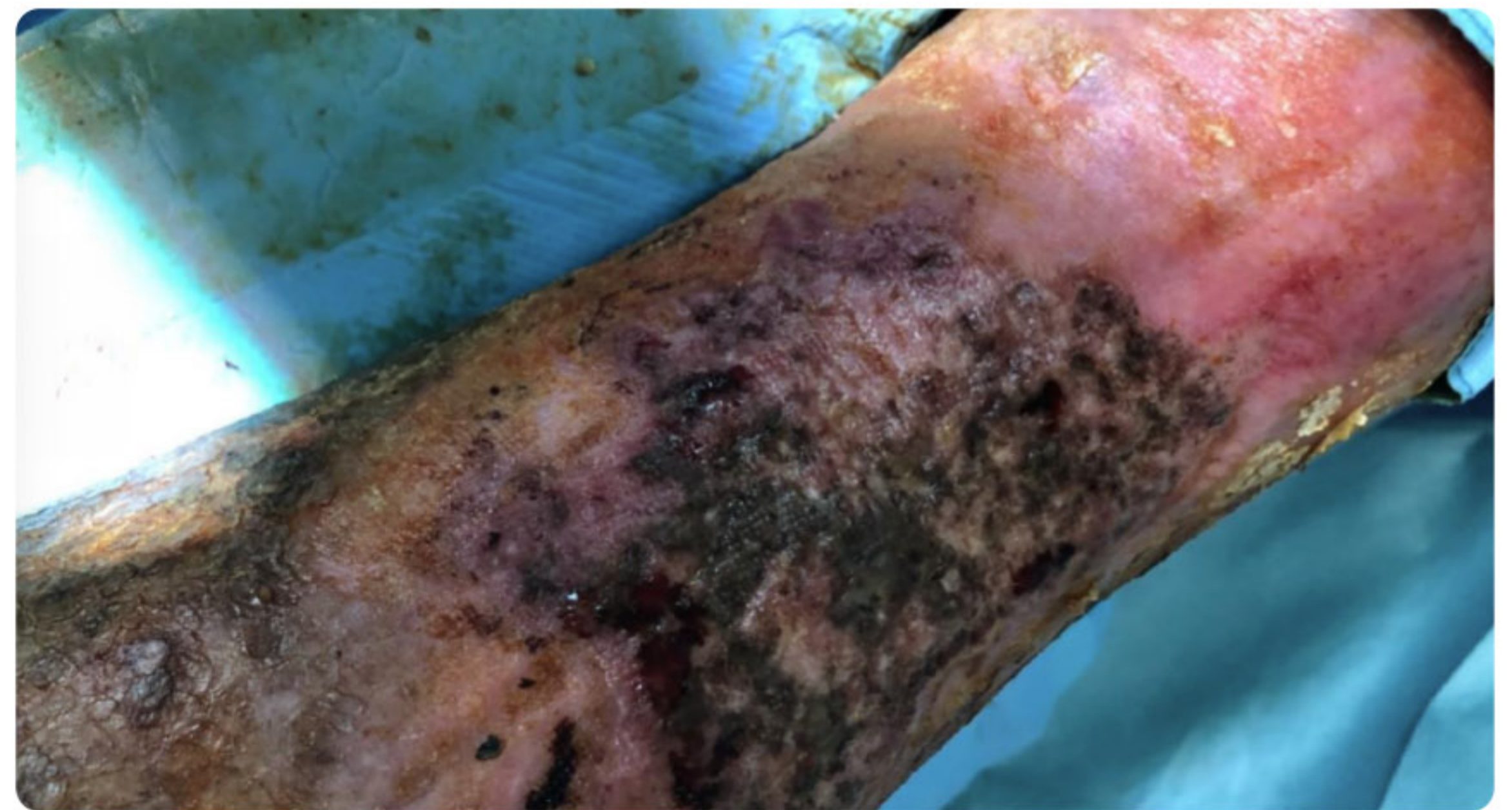


PROGRESS



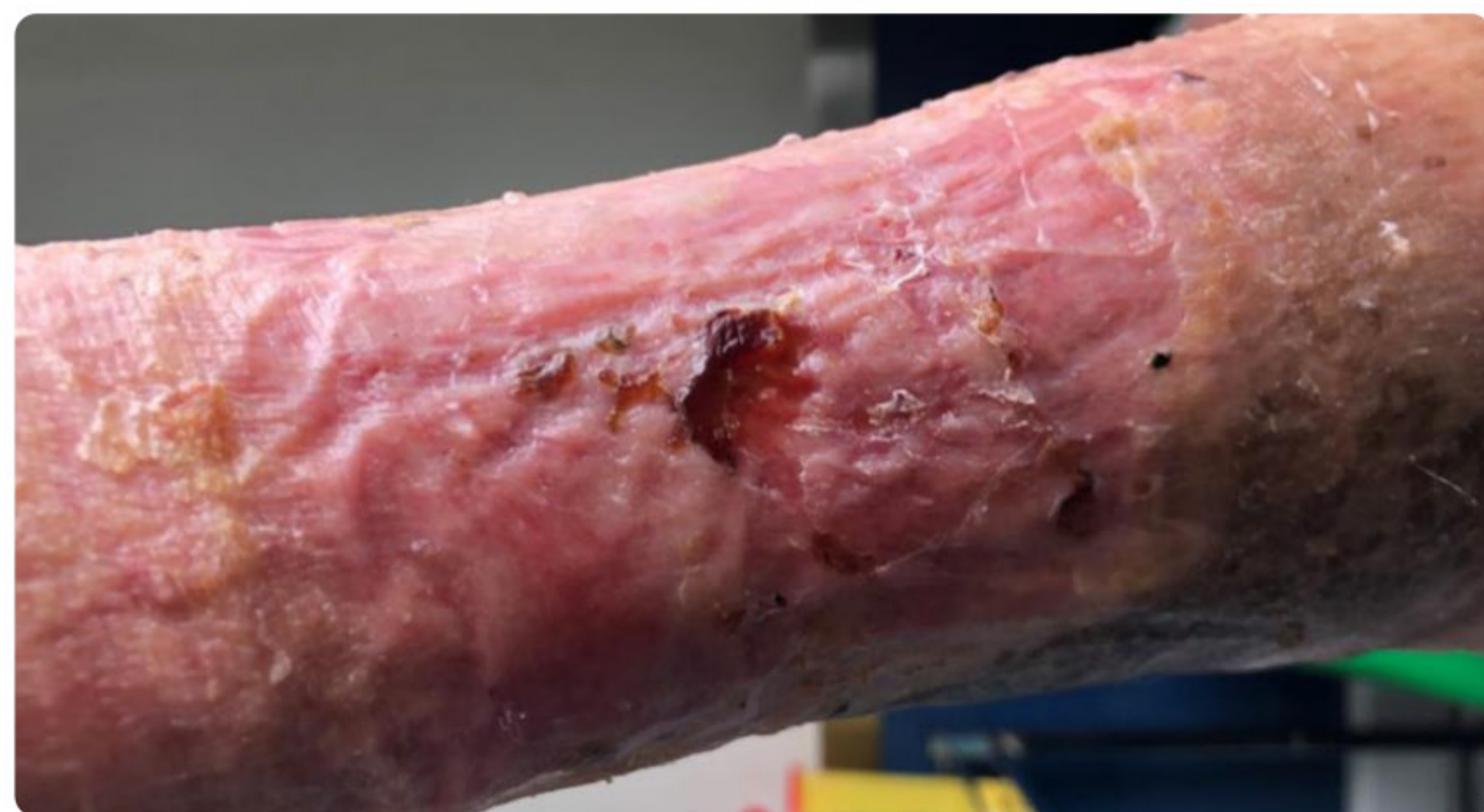A

Figure A: At Presentation



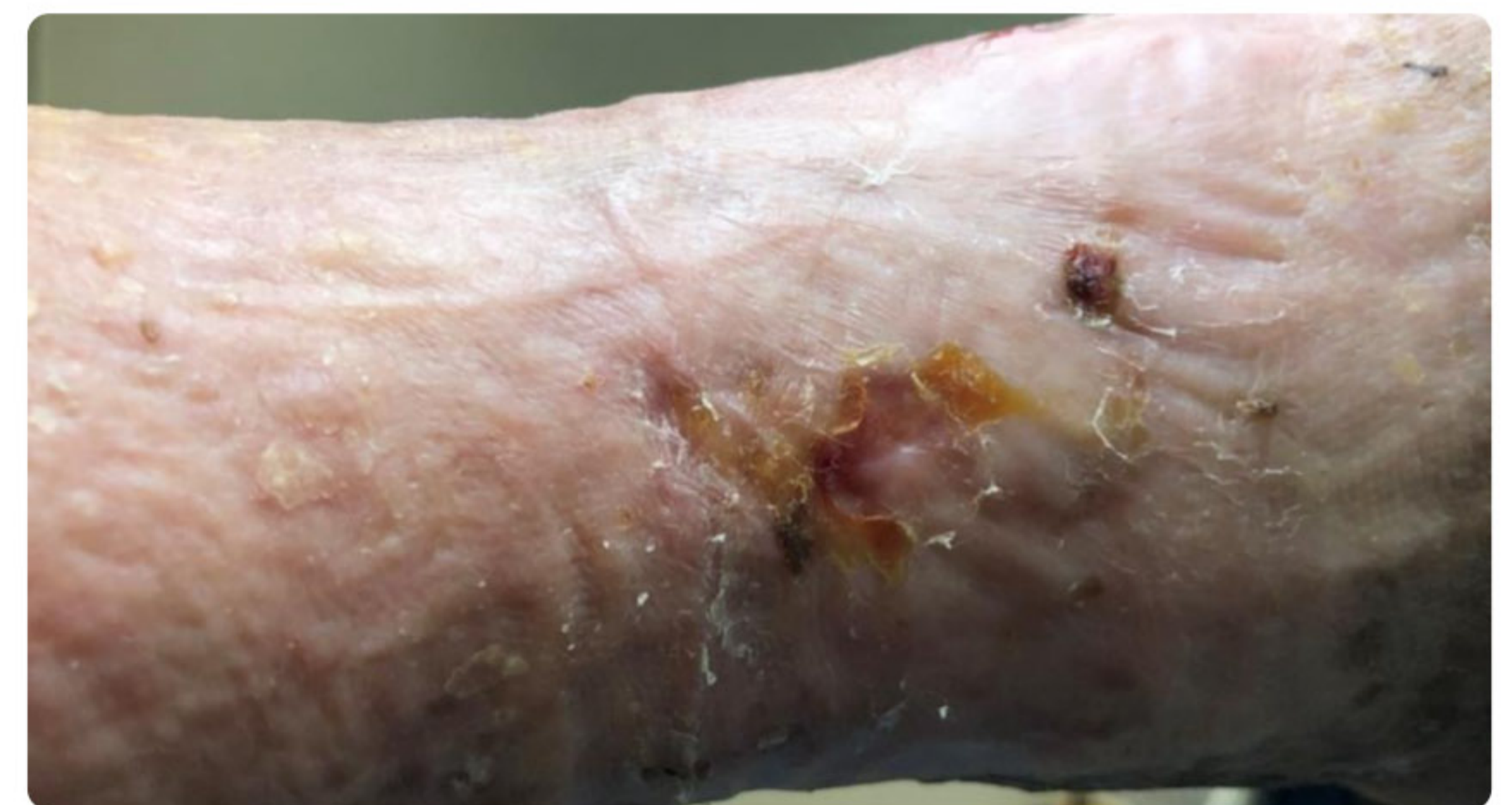B

Figure B: During DEBRICHEM



C

Figure C: 3 Weeks Post DEBRICHEM



D

Figure D: 6 Weeks Post DEBRICHEM



CASE 49

80-YEAR-OLD FEMALE WITH
BILATERAL VENOUS LEG ULCER

AUTHOR

S. AMESZ, DEVENTER ZIEKENHUIS,
NETHERLANDS

ETIOLOGY

VENOUS LEG ULCER



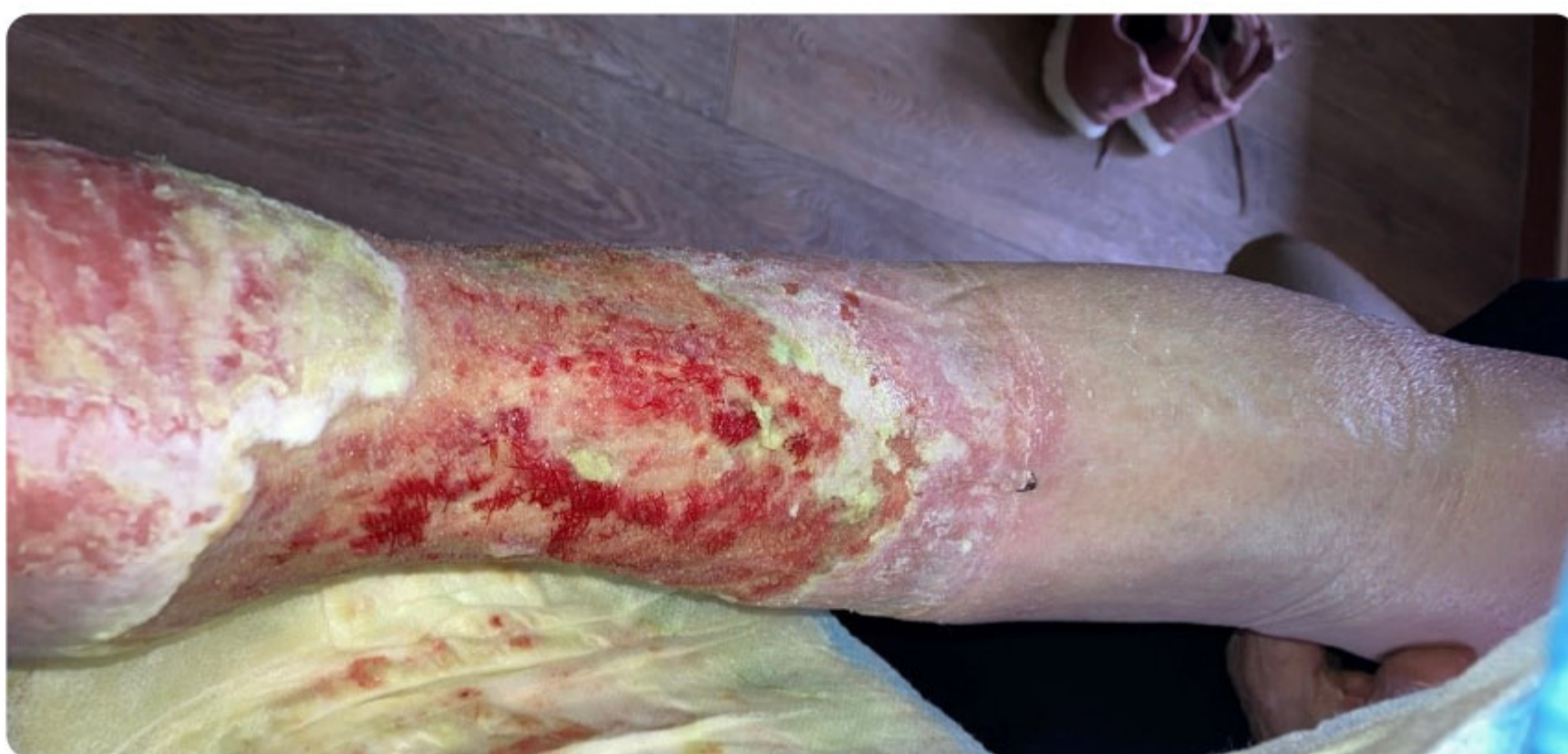GENERAL MEDICAL HISTORY

- ✓ Renal failure
- ✓ Coronaric artery disease
- ✓ Hypertheroid
- ✓ Diabetes Mellites
- ✓ Erysepelas
- ✓ Anemea

DESCRIPTION

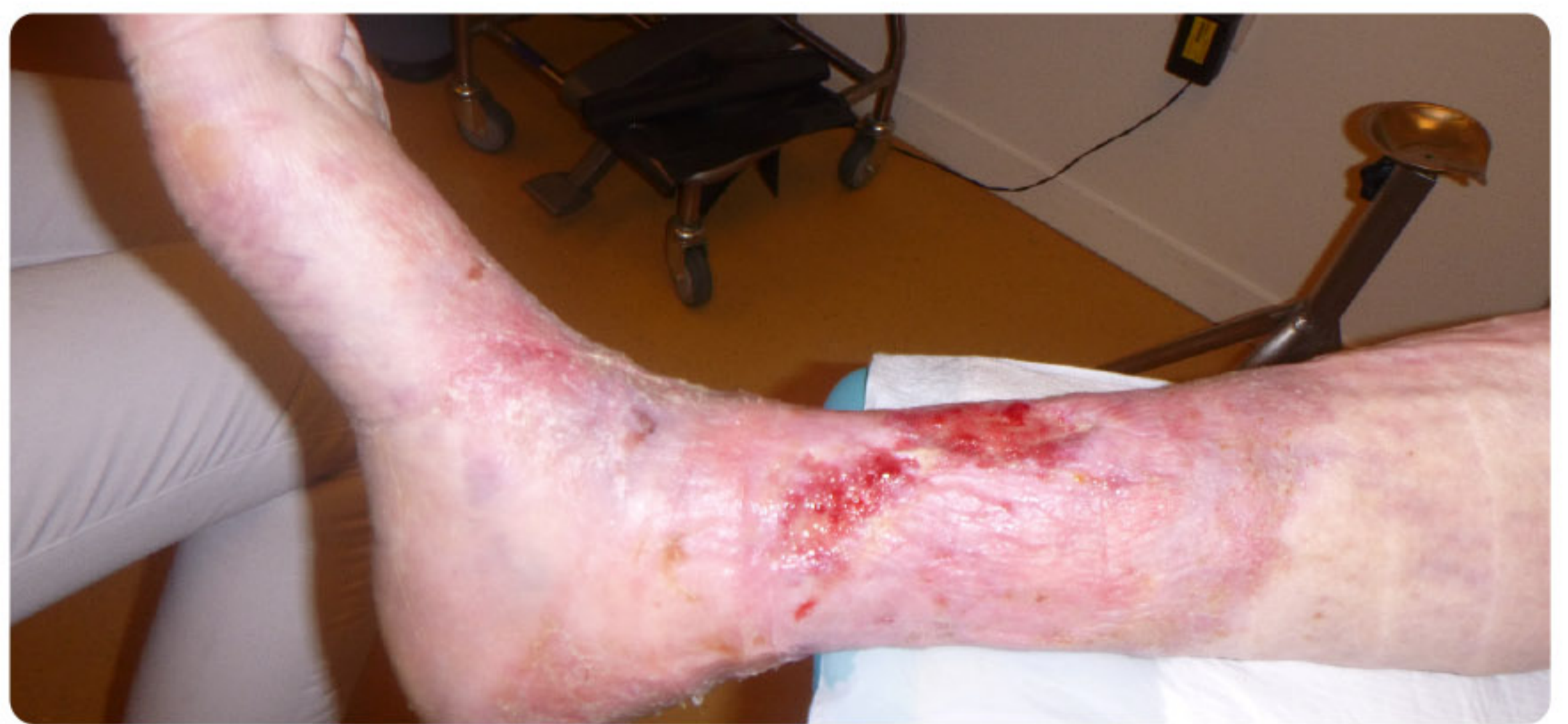The 80-year-old female patient presented with longstanding venous leg ulcers, which had been present for a decade. The ulcers were located bilateral (Figure A). Preceding DEBRICHEM, the patient received care involving the application of antimicrobial and absorptive dressings. No compression therapy was possible by severe wound pain. Following DEBRICHEM, notable progress was observed within the initial two-week period. The ulcers indicated a positive healing trajectory by granulating completely in the first 2 weeks (Figure B, right leg). Following DEBRICHEM treatment, a significant reduction in pain was reported by the patient. This alleviation of pain enabled the implementation of compression therapy. Continued utilization of antimicrobial dressings and compression therapy facilitated ongoing progress in wound healing. After nine weeks, the ulcers achieved complete healing (Figure C).

PROGRESS



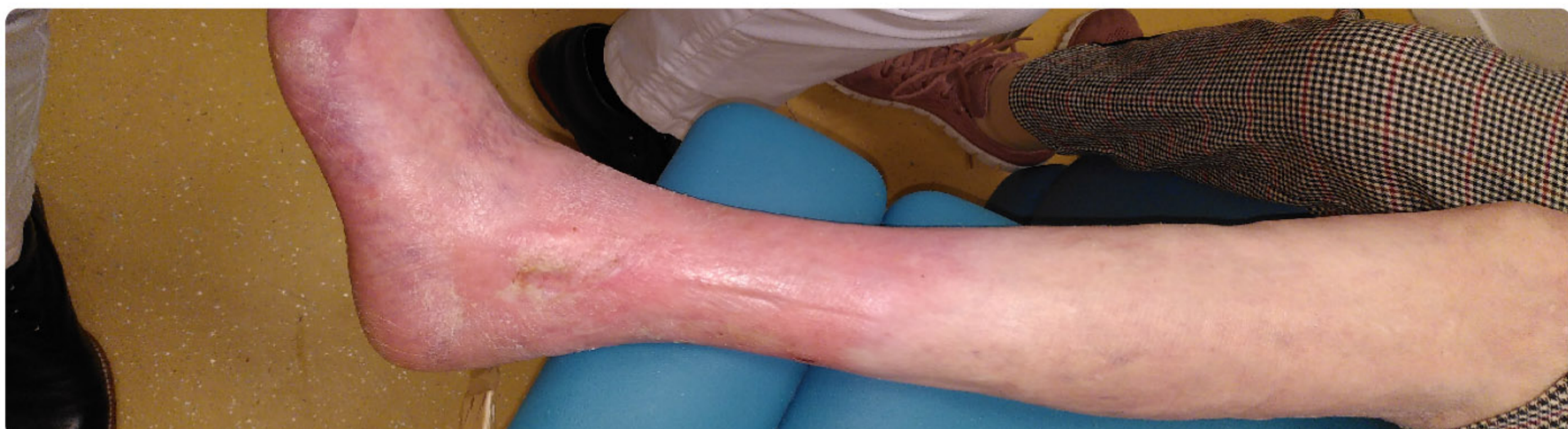
A

Figure A: At presentation



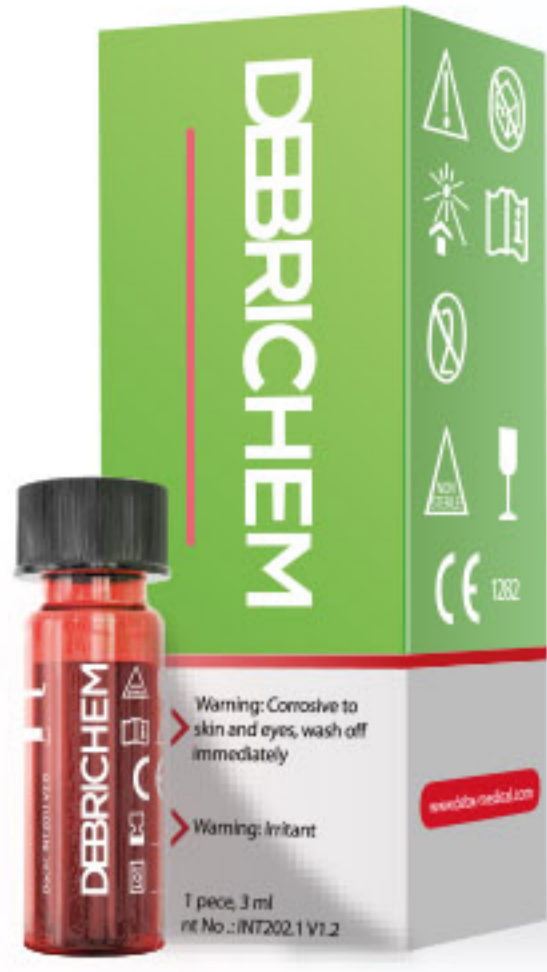B

Figure B: 2 weeks after DEBRICHEM



C

Figure C: 9 weeks post DEBRICHEM



CASE 55

49- YEAR-OLD MALE WITH A BILATERAL LOWER LEG VENOUS ULCER

AUTHOR

PRITI BHATT, TISSUE VIABILITY LEAD COMMUNITY SERVICES AT GUY'S AND ST THOMAS' NHS FOUNDATION TRUST

ETIOLOGY

VENOUS LEG ULCER



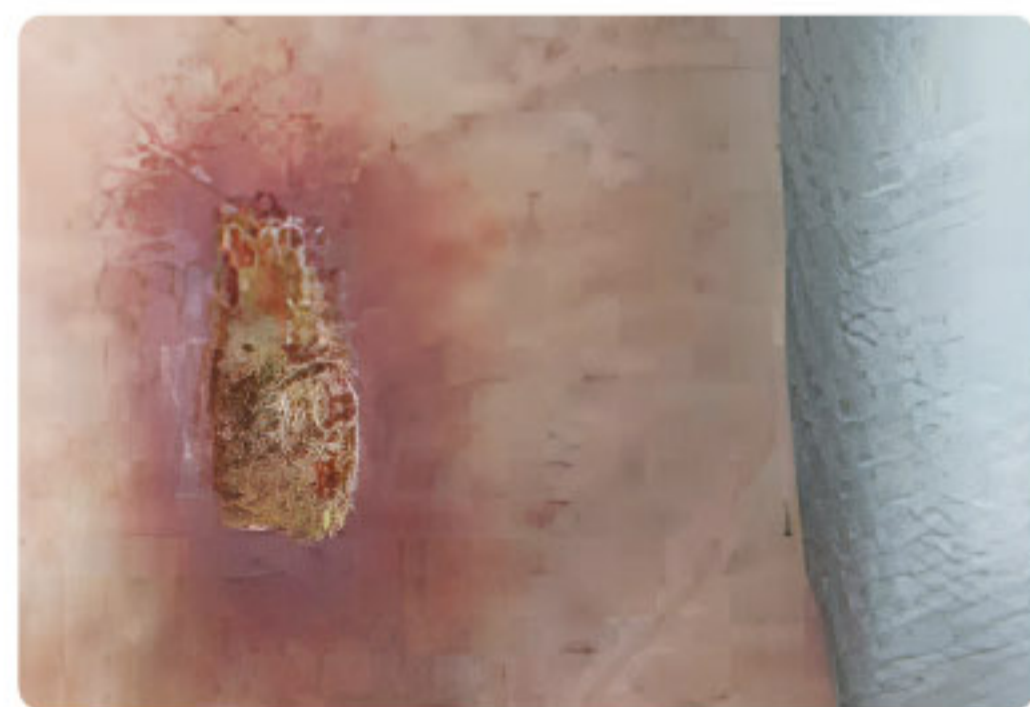DEB^x MEDICAL GENERAL MEDICAL HISTORY

- ✓ Varicose veins in both legs
- ✓ Varicose eczema
- ✓ Vein damage due to intravenous drug use
- ✓ Asthma
- ✓ Penicillin allergy

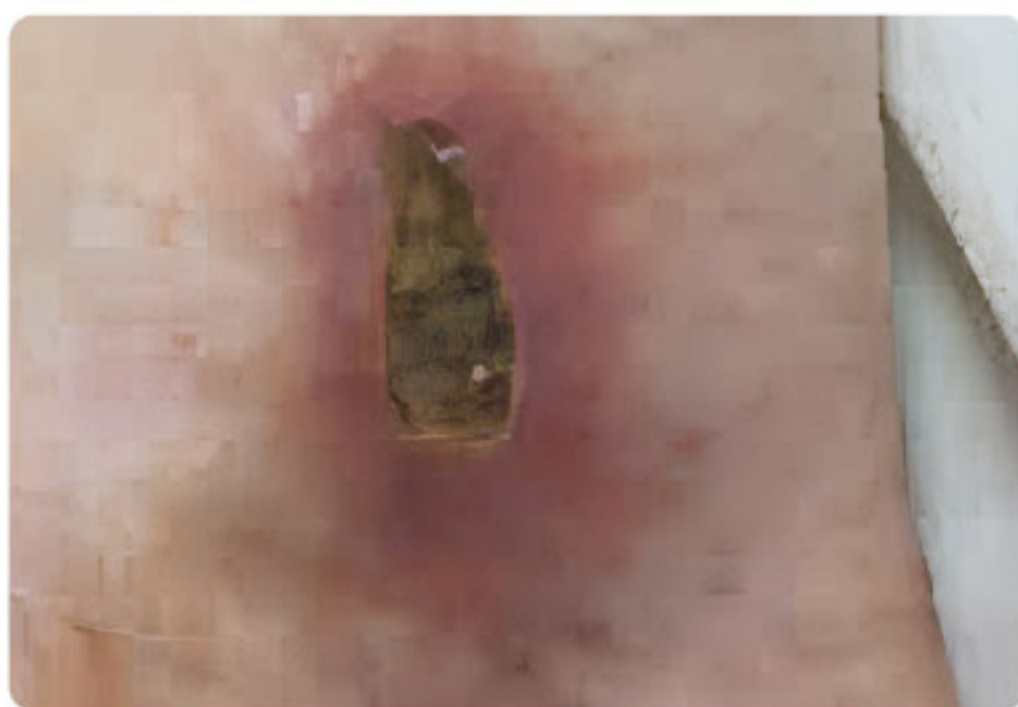DEB^x MEDICAL DESCRIPTION

A 49-year-old man presented with lesion predominantly affecting the left medial malleolus, persisting for an extensive 11 years.(Figure A) His medication regimen includes an asthma inhaler, topical steroid for eczema, steroid cream, and 50:50 white paraffin ointment. The lesions exhibited intermittent ulceration for 11 years, with temporary success following a venous stent procedure in the right leg but subsequent failure after an unsuccessful attempt in the left leg. The lesions causes pain, limited mobility, difficulty in working, negative effects on family life, and low mood. DEBRICHEM was initiated due challenge the recurrent infections, and a lack of progression despite other treatments for 2 years.(Figure B) Upon presentation, the wound care regimen included silver foam and full compression bandages or two-layer hosiery kits. Previous treatments encompassed a variety of modalities such as enzyme alginogel, honey tulle, hydrophobic microbial-binding foam, polymeric membrane, silver Hydrofiber, silver sulfadiazine, and mechanical debridement pads. Post-Debrichem, the regimen was modified to include silver foam alongside full compression bandages progressing wound healing showing good signs towards full closure at week 10 (Figure C)

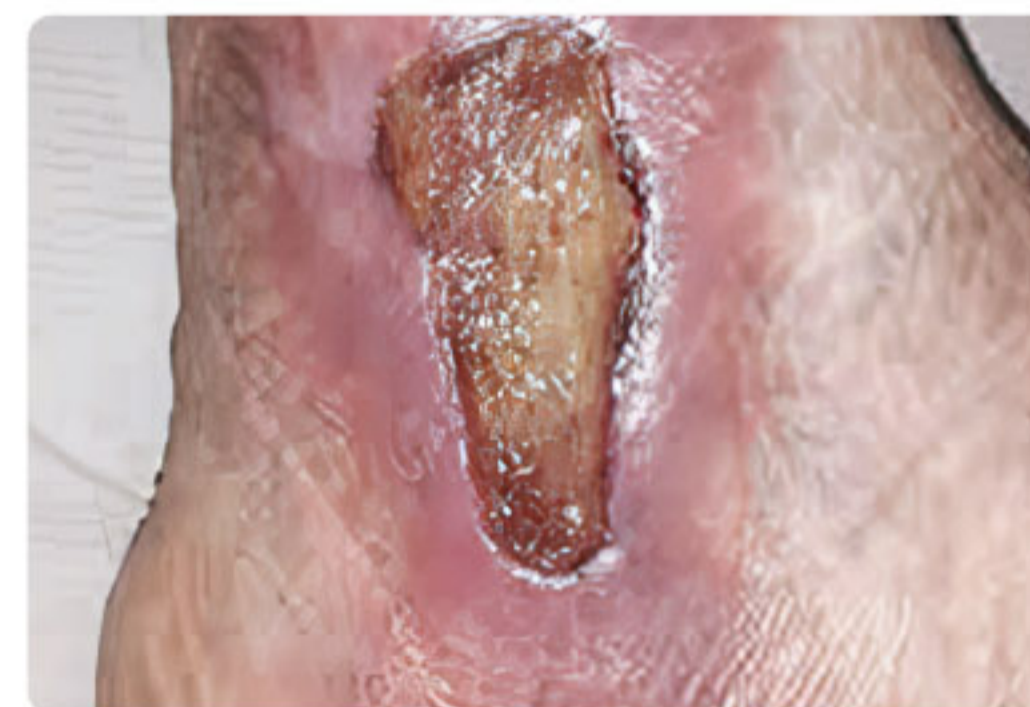DEB^x MEDICAL PROGRESS



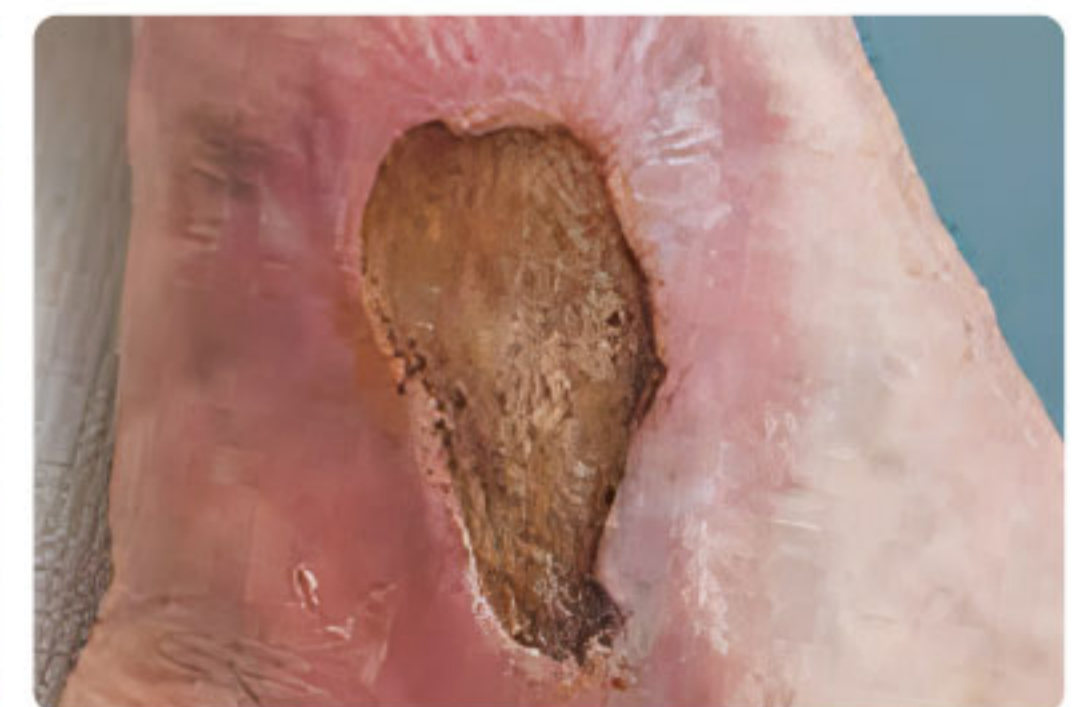1. Figure A: At presentation



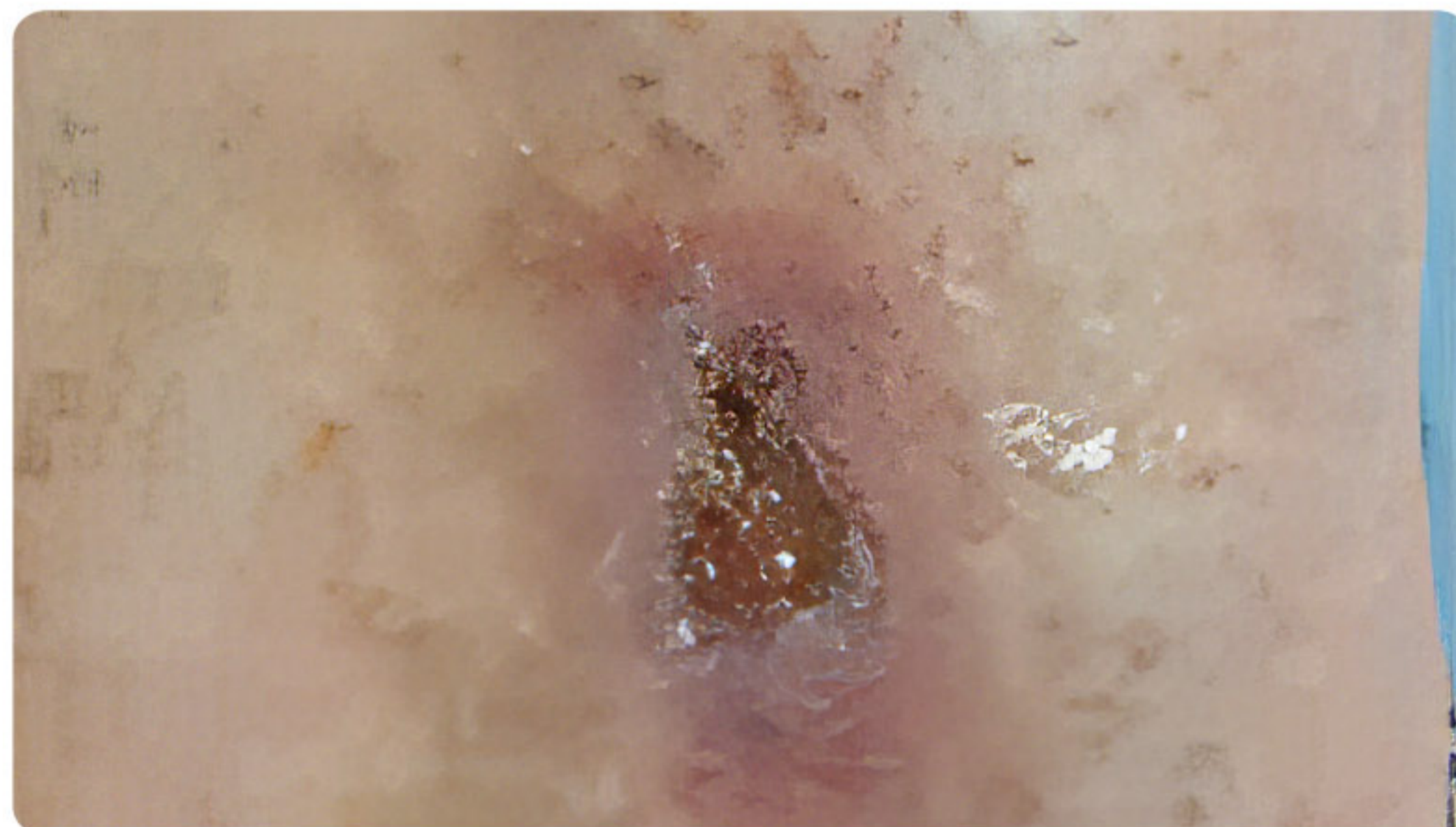
2. Figure B: After DEBRICHEM treatment



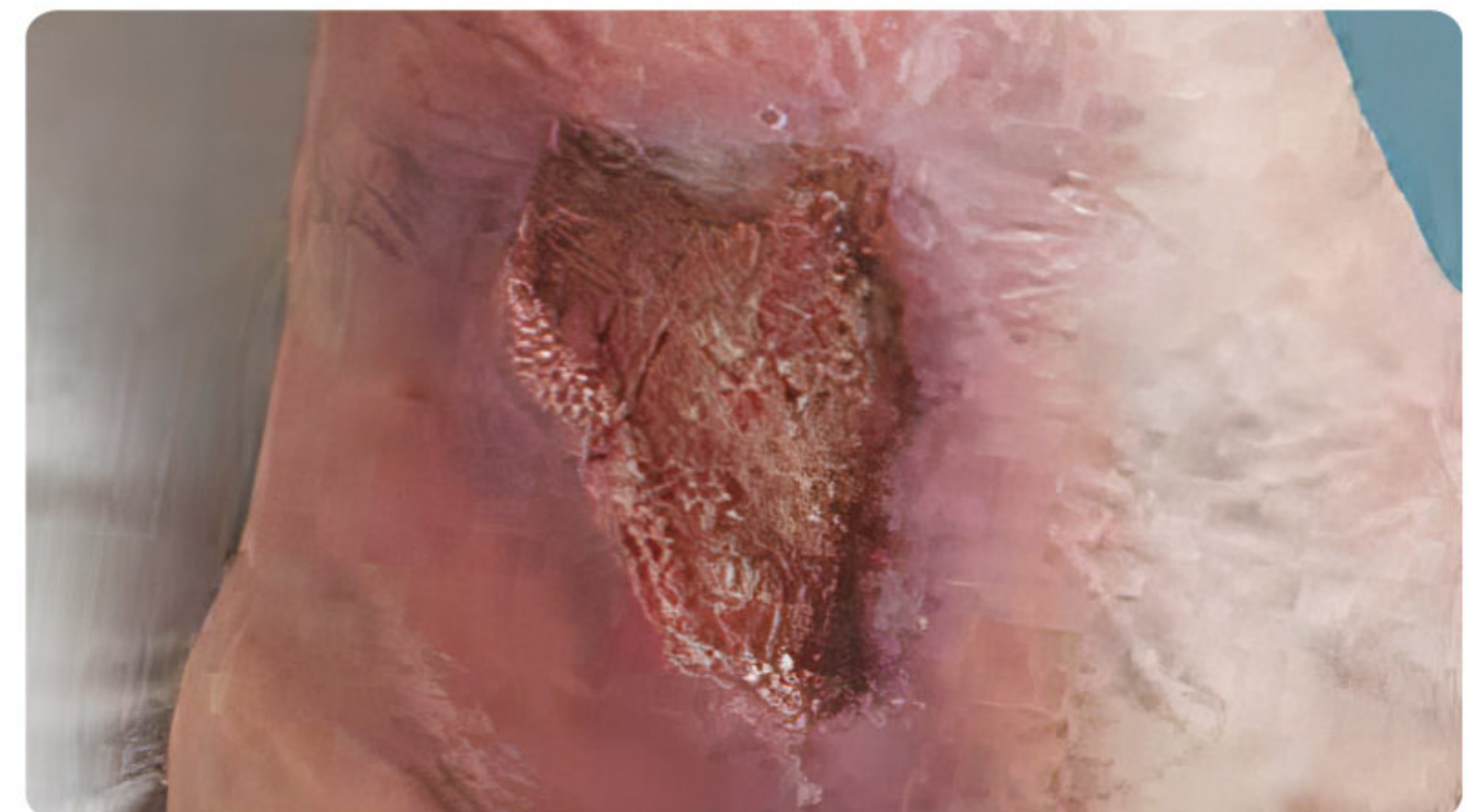3. Figure A: At presentation



4. Figure B: After DEBRICHEM treatment



5. Figure C: 10 weeks after DEBRICHEM



6. Figure C: 10 weeks after DEBRICHEM



CASE 11

83- YEAR-OLD FEMALE WITH
GANGRENOUS DIABETIC FOOT ULCER

AUTHOR

DR. A.COGO, VILLA BERICA, ITALY

ETIOLOGY

DIABETIC FOOT ULCER



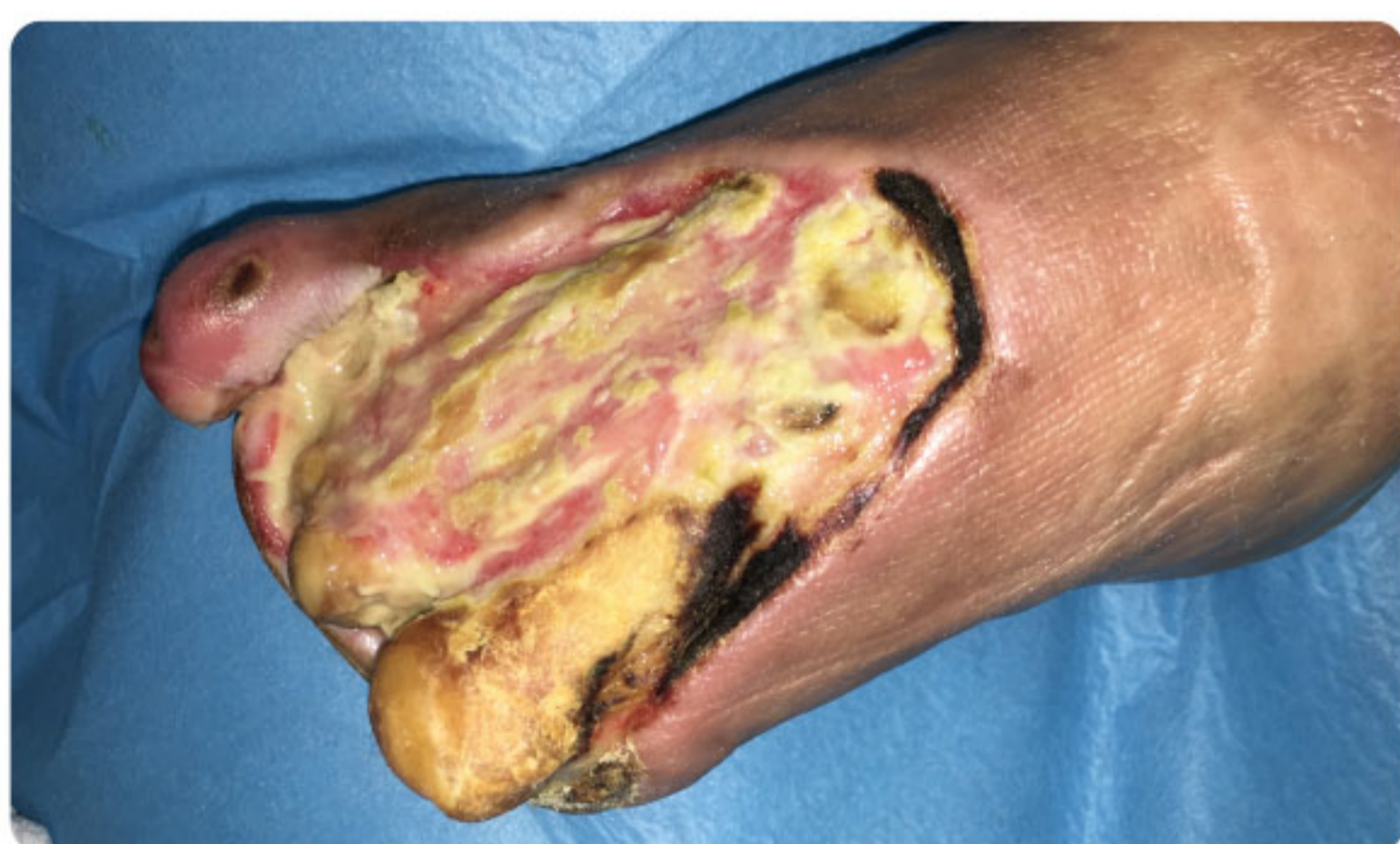GENERAL MEDICAL HISTORY

- ✓ Diabetes mellitus
- ✓ Ischemic stroke (bed ridden)
- ✓ Forefoot gangrene
- ✓ Amputation followed by full dehiscence

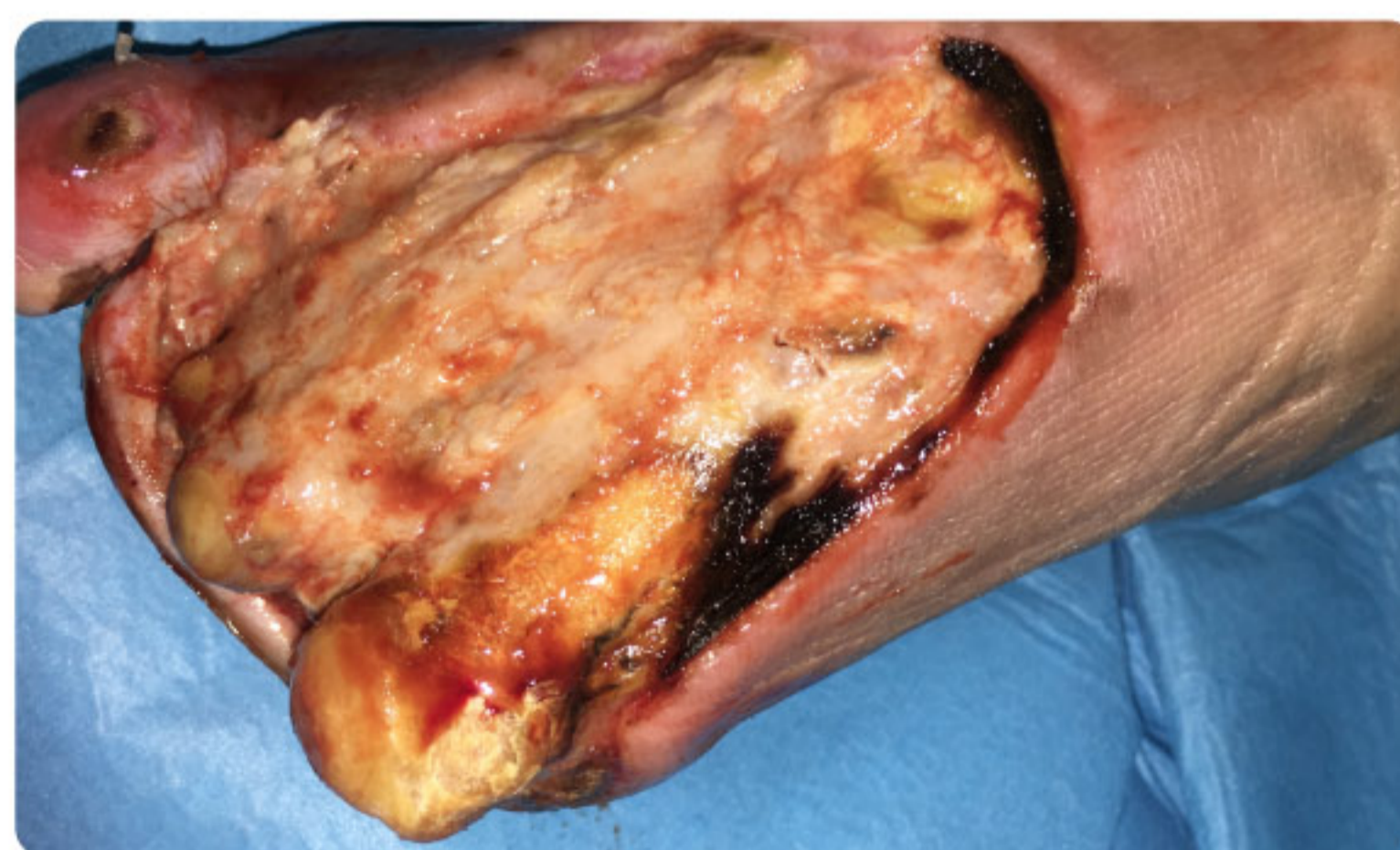DESCRIPTION

The patient entered the clinic with a lesion that remained infected after partial amputation due to gangrene and where the surgical lesion showed full dehiscence (Figure A). This wound bed has showed no improvement despite a good arterial bloodflow (assessed with ultrasound) and despite silver and iodine infused dressings. The patient went through several cycles of antibiotic treatment to reduce bacterial load on the wound bed but this showed no regression towards healing as well. The patient, known with long lasting diabetes mellitus and bed ridden due to an ischemic stroke receive one application of DEBRICHEM treatment. The wound bed showed improvement on the edges immediately after DEBRICHEM application (Figure B). Considering the effect of DEBRICHEM a minor additional bone resection has been executed 7 days post DEBRICHEM application to improve the wound bed and bone tissue (Figure C). Following the minor bone resection vacuum therapy was initiated. In three weeks after the resection, 28 days post DEBRICHEM application the wound bed showed good granulation (Figure D). At granulation the vacuum therapy was cancelled and biweekly Vaseline dressing change was initiated. At 60 days after the DEBRICHEM application the wound bed showed epithelization and the foot has good improvement (Figure E). After a good amount of time a long term follow up at 9 month after the DEBRICHEM application the lesion shows complete healing (Figure F).

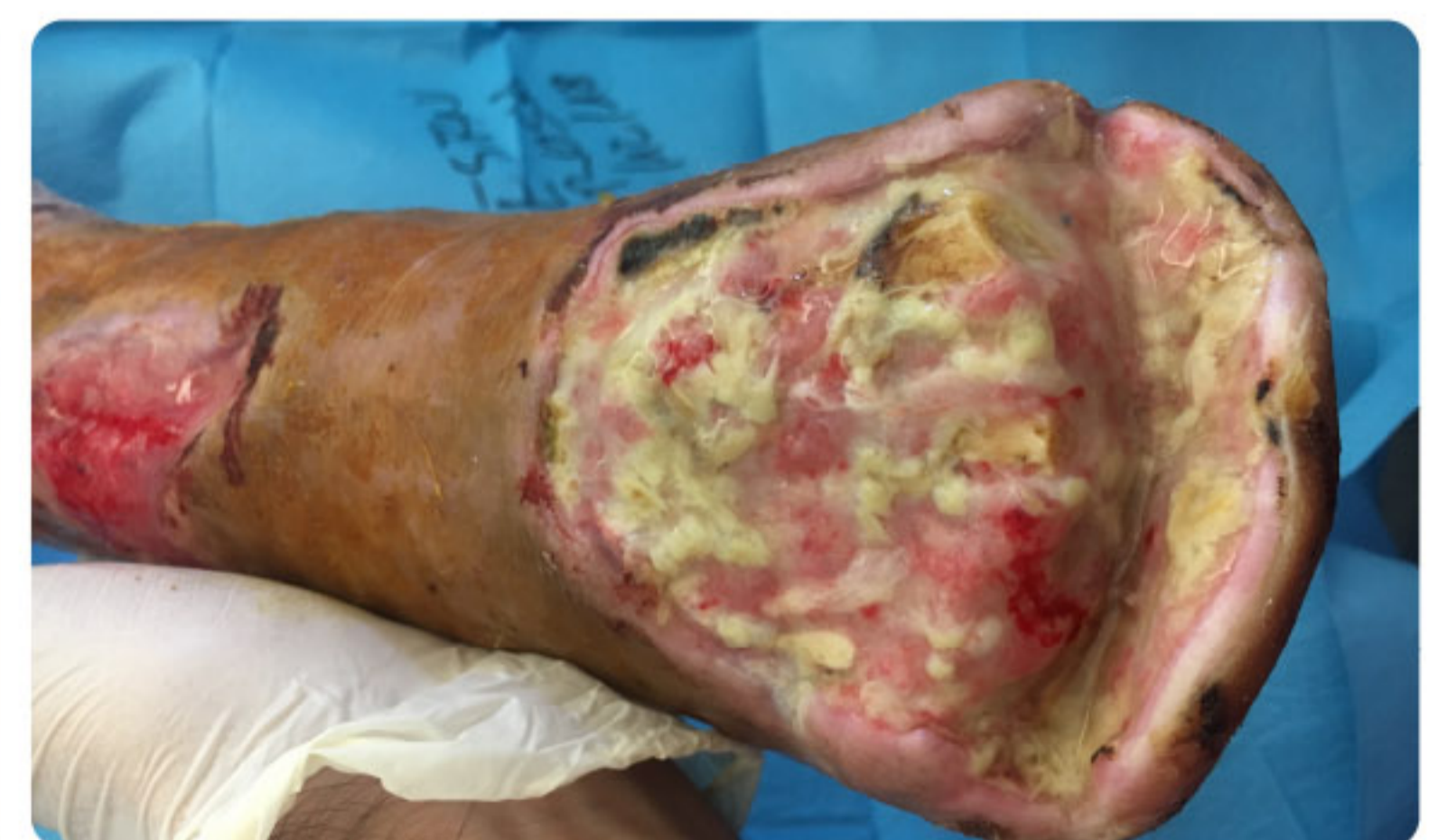PROGRESS



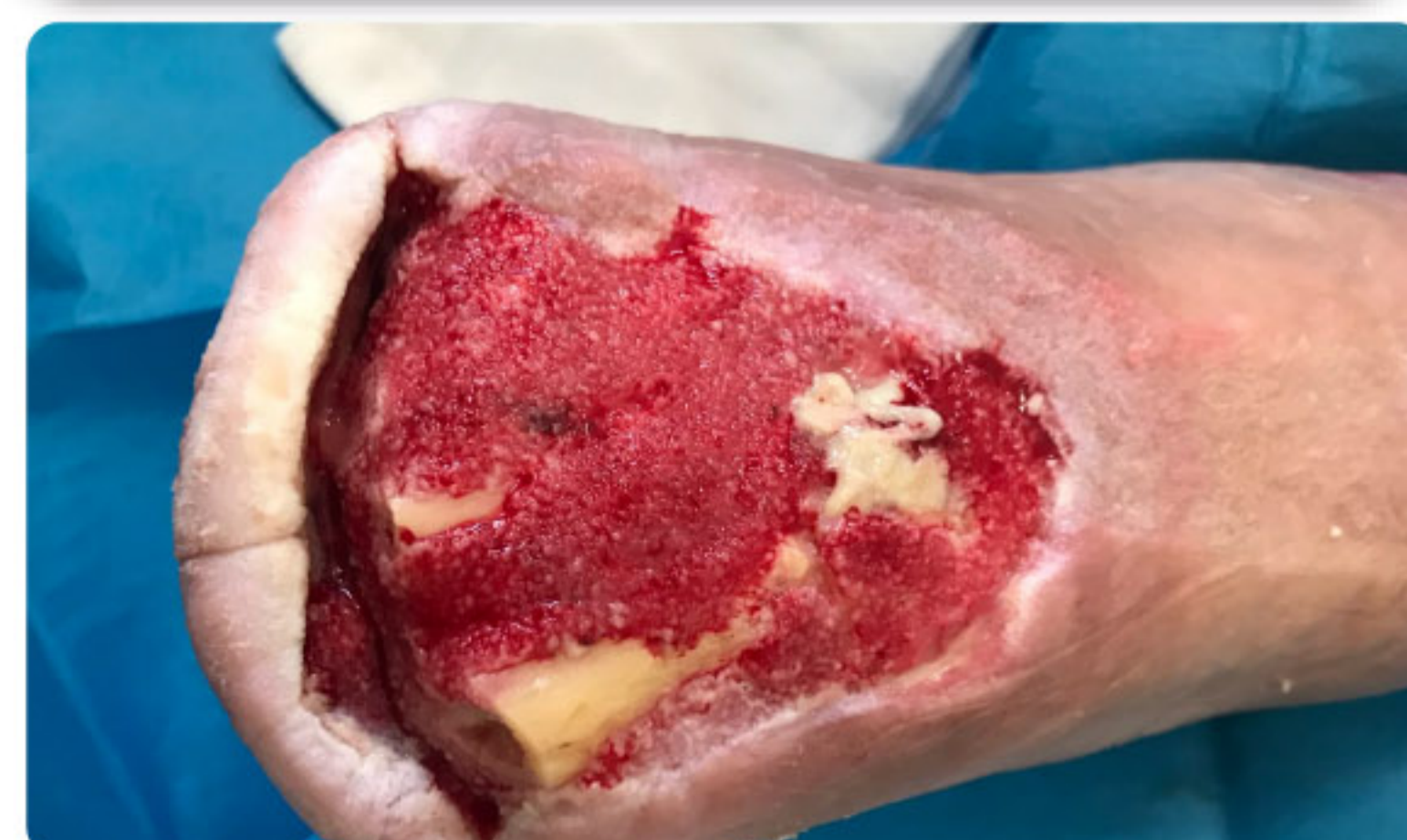A Figure A: Presentation at clinic



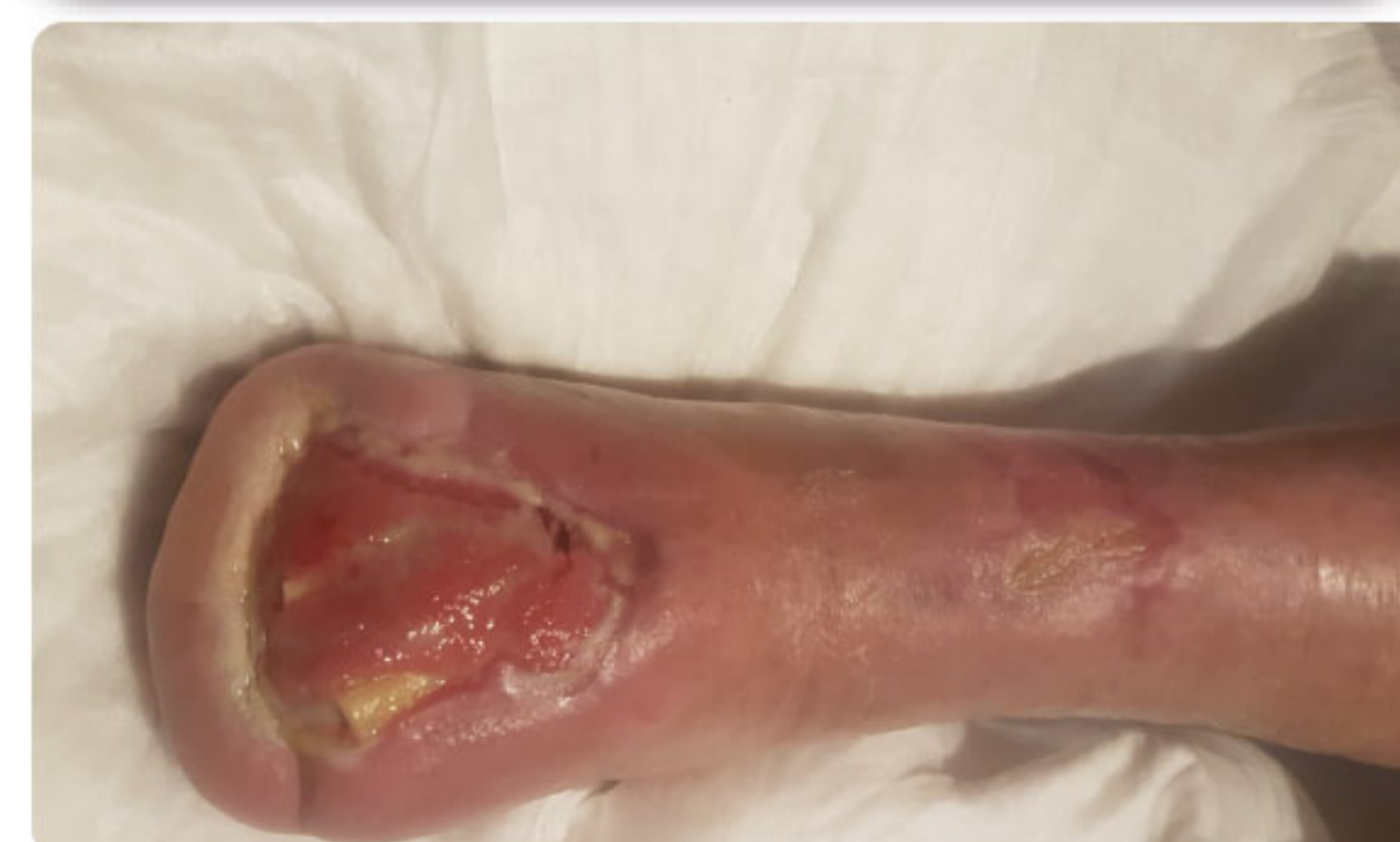B Figure B: Post DEBRICHEM application



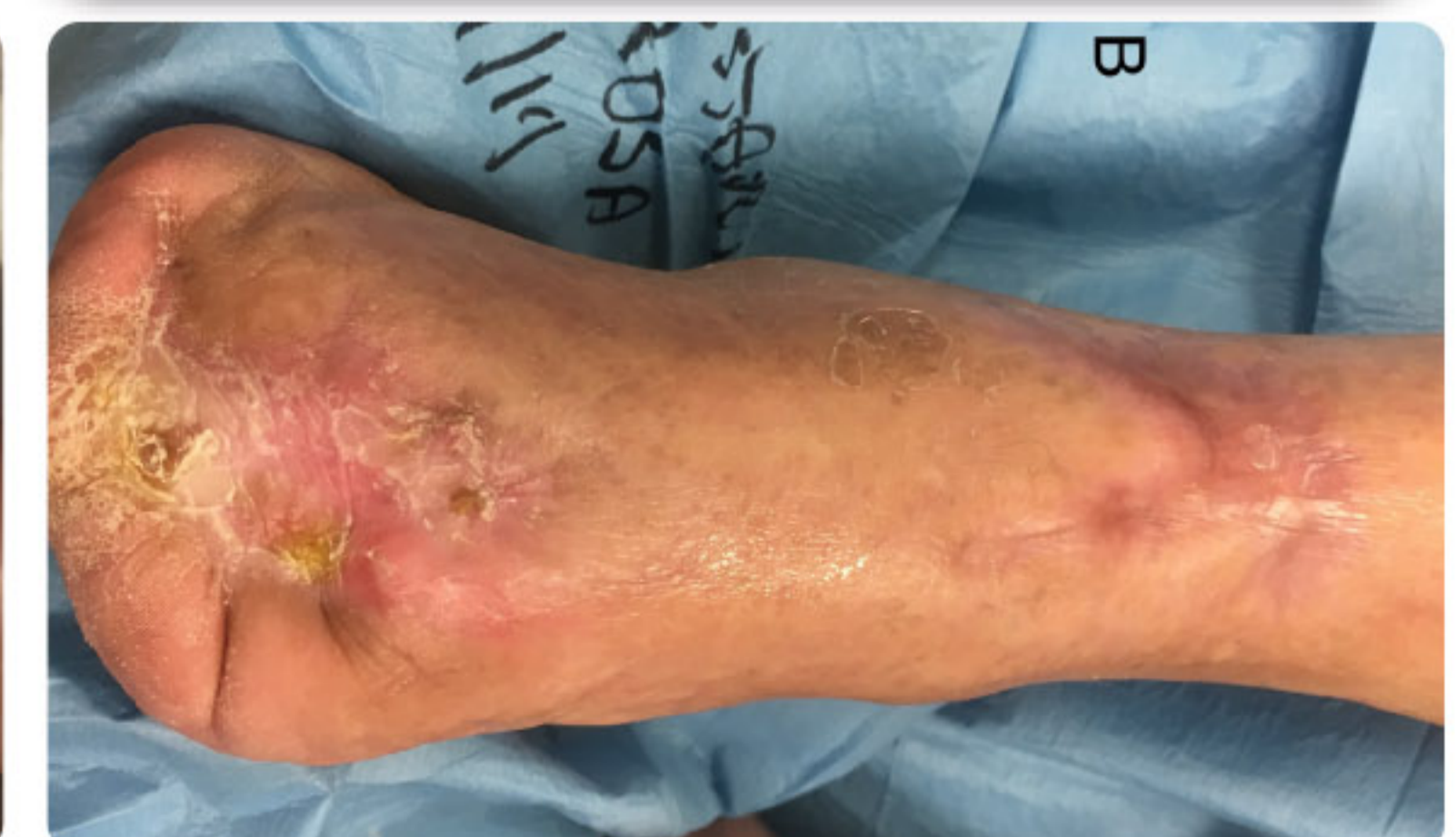C Figure C: Bone resection at day 7 post DEBRICHEM



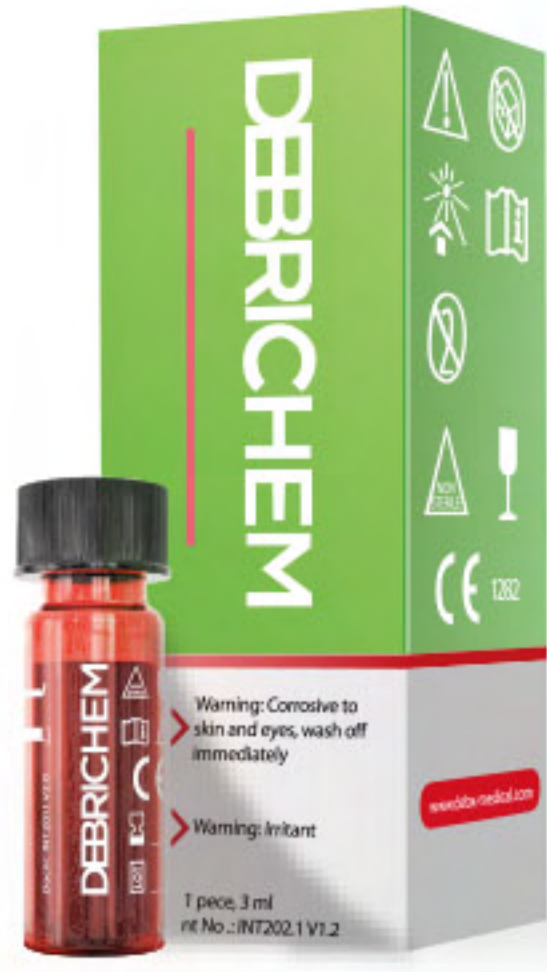D Figure D: 28 days after DEBRICHEM application



E Figure E: 60 days post DEBRICHEM



F Figure F: Long term follow-up (9 months)



CASE 29

67- YEAR-OLD FEMALE WITH
A DIABETIC ULCER ON RIGHT FOOT

AUTHOR

PROF. H. NAIR,
HOSPITAL KUALA LUMPUR, MALAYSIA

ETIOLOGY

DIABETIC FOOT ULCER



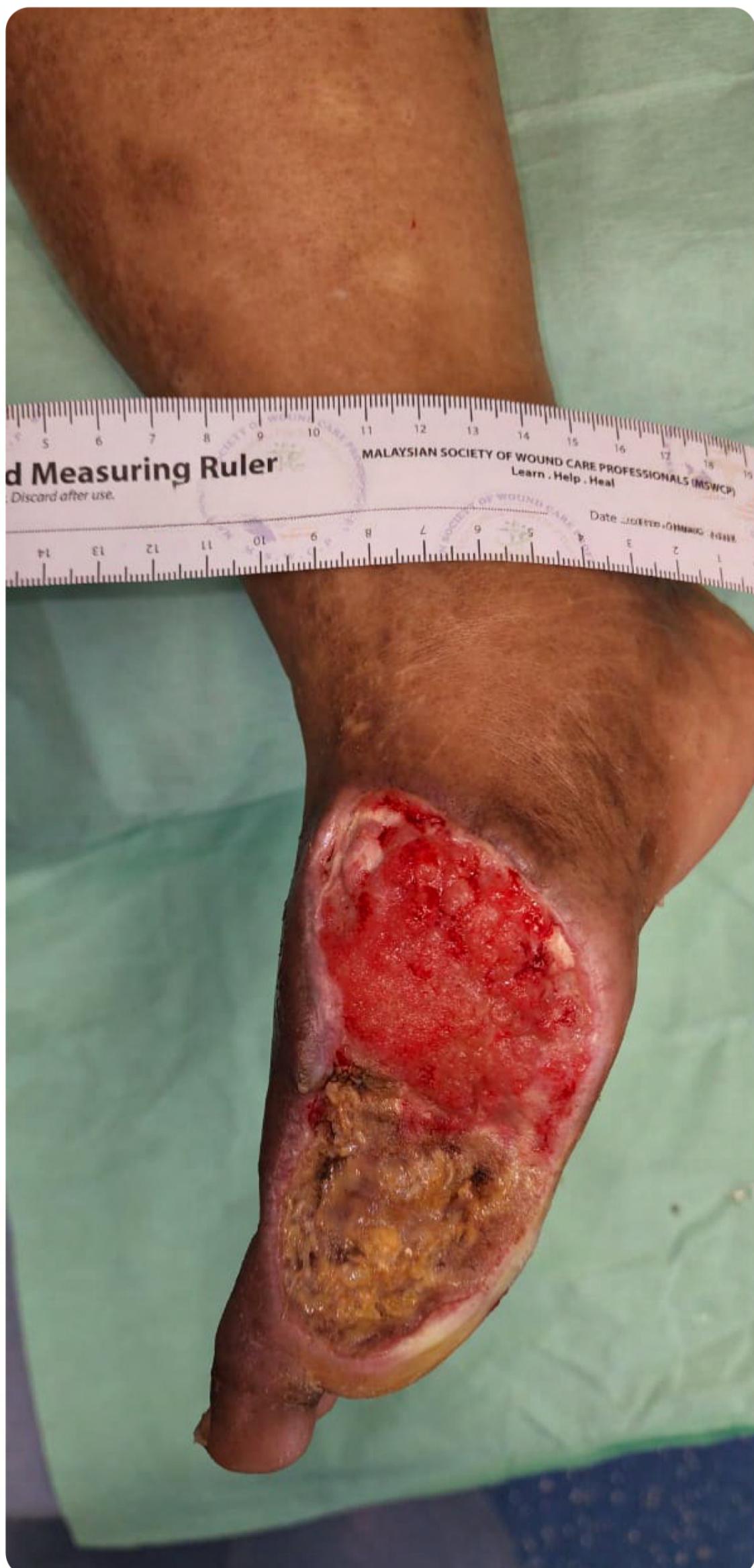GENERAL MEDICAL HISTORY

- ✓ Diabetes Mellitus
- ✓ Hypertension
- ✓ Dyslipidaemia
- ✓ Ischemic heart disease

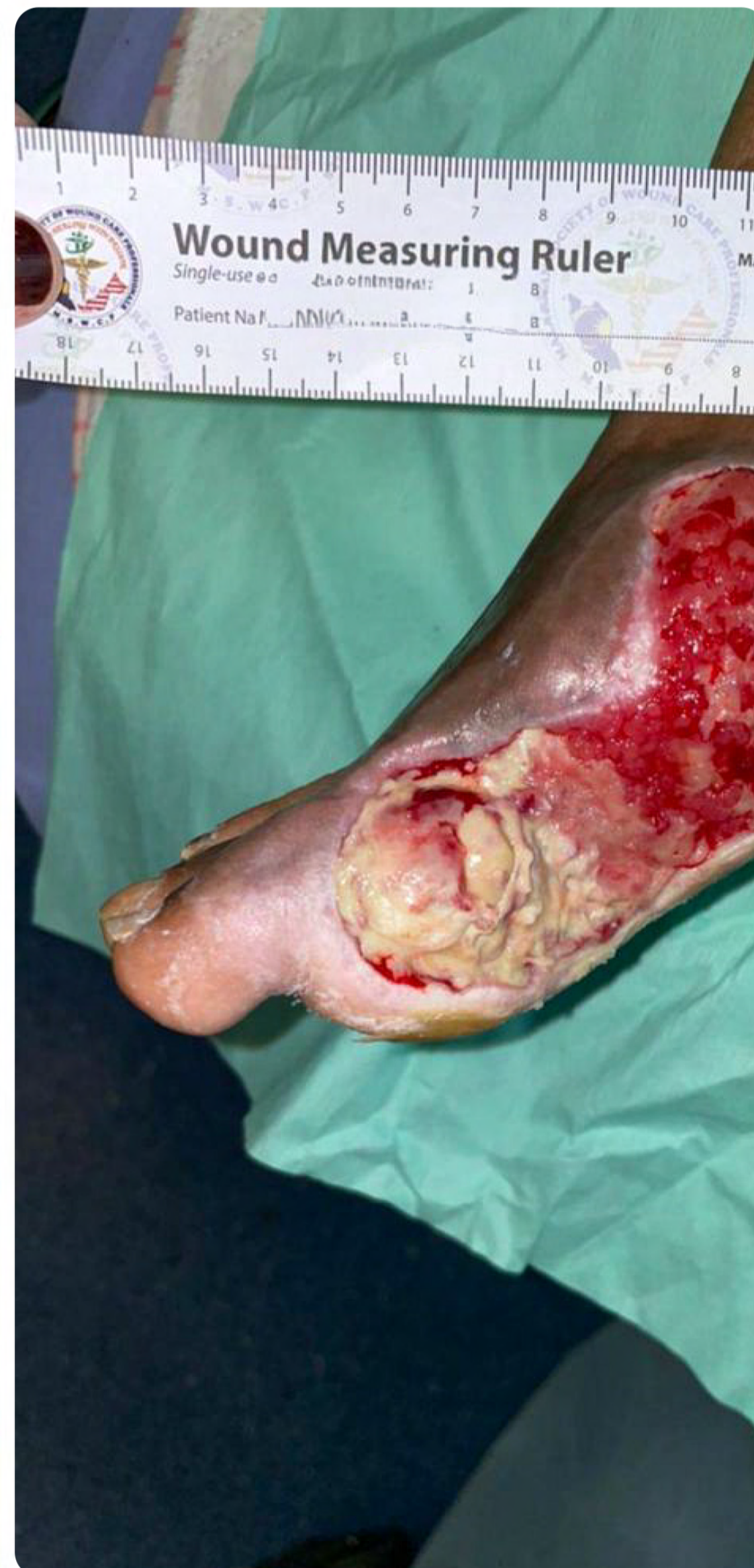DESCRIPTION

Patient with underlying diabetes mellitus, presented with a diabetic ulcer on the right foot, which underwent sharp debridement and a ray resection. 5 weeks post-amputation, the wound measured 9.5 x 5 cm. It had been treated with Manuka honey dressing and hydrogel, with limited success (Figure A). DEBRICHEM was initiated as the next treatment for the diabetic foot ulcer. Despite being on aspirin, no bleeding was observed during treatment with DEBRICHEM. The patient was also taking insulin, Cardiprin, felodipine, and linofer. Follow-up treatment consisted of changing Vaseline gauze at least twice a week. In 2 weeks, full granulation of the wound bed was observed (Figure B). The wound remained granulated and showed good indications of healing at the one-week follow-up visit. See figure C for the 7th week visit. At week 13 post-DEBRICHEM, the wound had completely reepithelialised (Figure D). The successful use of DEBRICHEM in this patient with multiple comorbidities and medication use highlights its potential as a safe and effective treatment option for diabetic foot ulcers.

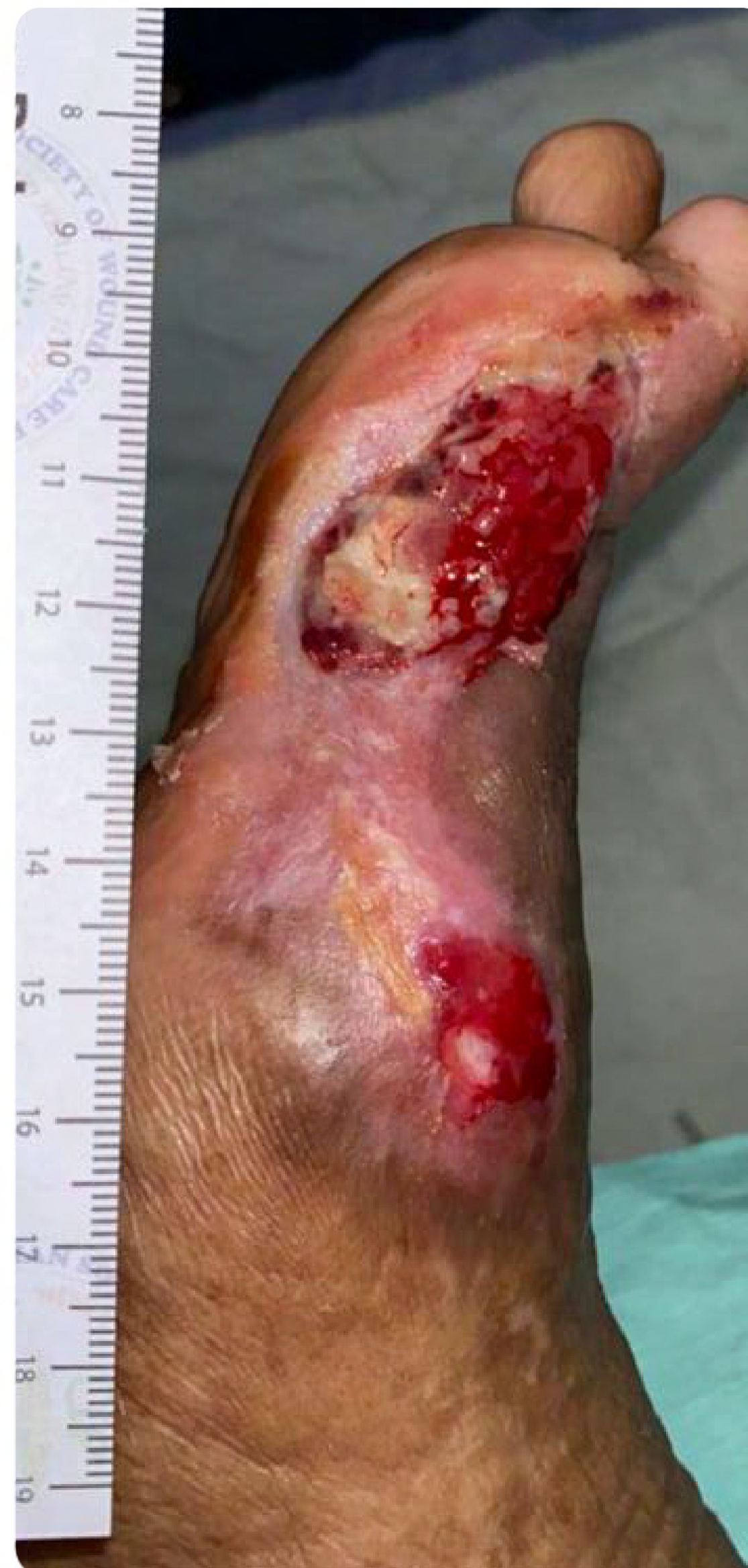PROGRESS



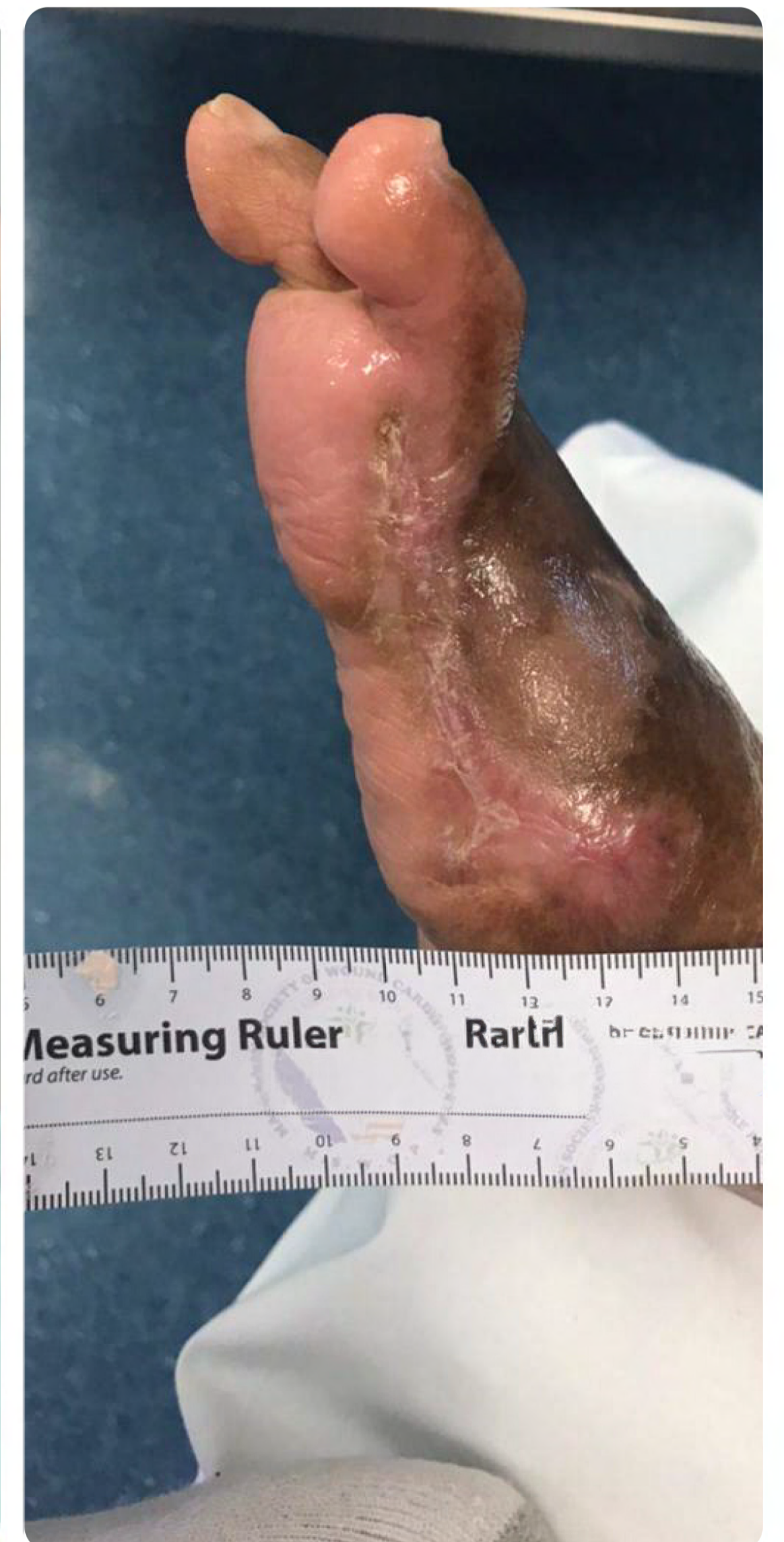1. Figure A: Wound presented prior to DEBRICHEM application



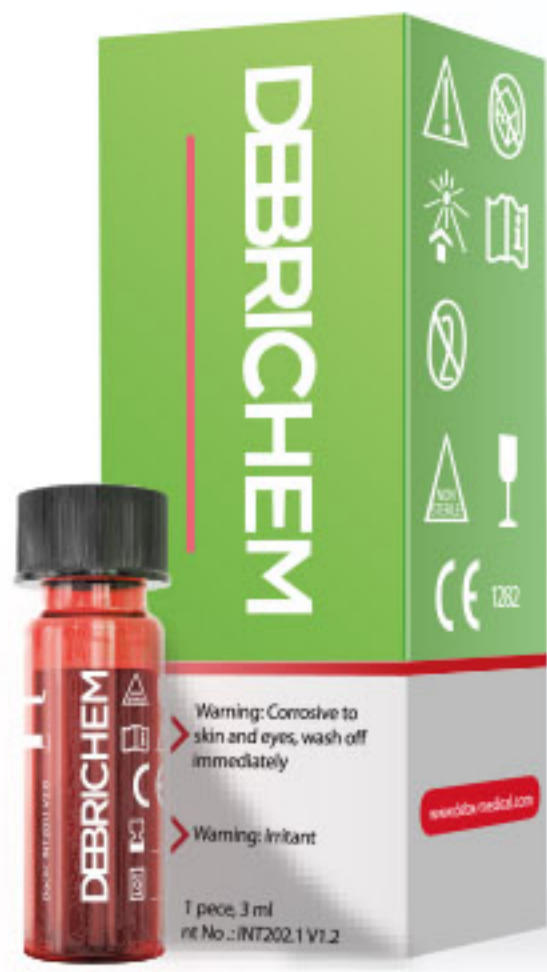2. Figure B: Wound 2 weeks Post-DEBRICHEM application



3. Figure C: Wound 7 weeks Post-DEBRICHEM application



4. Figure D: Wound 13 weeks Post-DEBRICHEM application



CASE 42

62- YEAR-OLD FEMALE WITH A
DIABETIC ULCER ON LEFT FOOT

AUTHOR

PHRAMONGKUTKLAO HOSPITAL, THAILAND

ETIOLOGY

DIABETIC FOOT ULCER



GENERAL MEDICAL HISTORY

- ✓ Diabetes mellites
- ✓ Second toe amputation
- ✓ Dyslipidaemia
- ✓ Hypertension

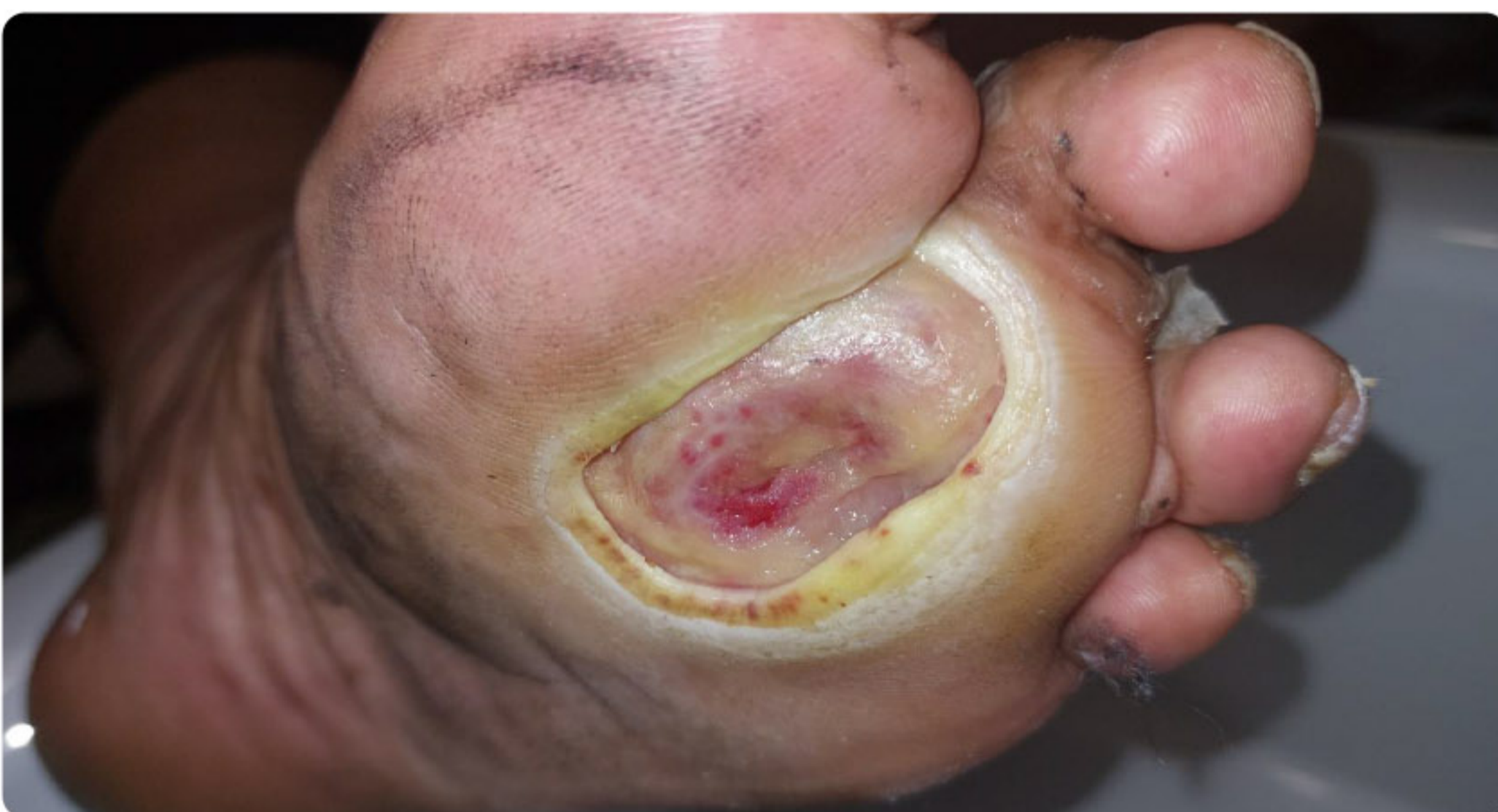DESCRIPTION

A 62-year-old female with a history of Diabetes mellites, dyslipidaemia and hypertension presented with an ulcer on the left foot. This diabetic foot ulcer was located next to a previous amputated toe of which the surgical wound has completely healed (Figure A). The diabetic foot ulcer was treated with DEBRICHEM. Multiple bacteria were identified in the ulcer, among which: Proteus mirabilis, Staphylococcus aureus, Pseudomonas aeruginosa. Initial treatment with DEBRICHEM resulted in significant improvement of the ulcer after 1 week (Figure B).

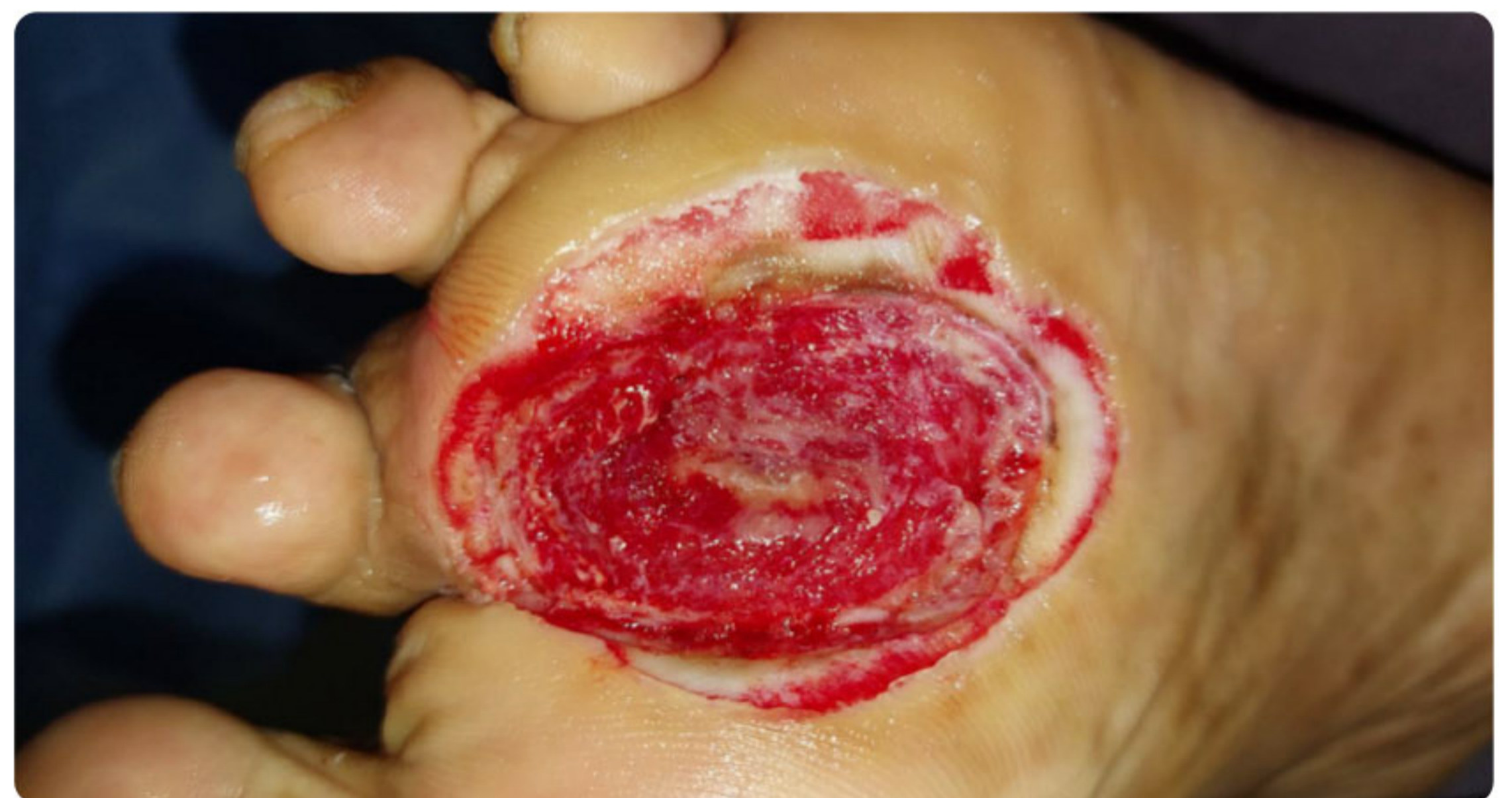After 2 months post-application the ulcer progressed further into wound healing (Figure C).

After 4 months the ulcer showed almost complete closure. It has been treated with standard of care dressing to control the right moisture balance to maintain optimal wound environment and facilitate healing, in addition offloading was done to have good perfusion to the wound bed (Figure D).

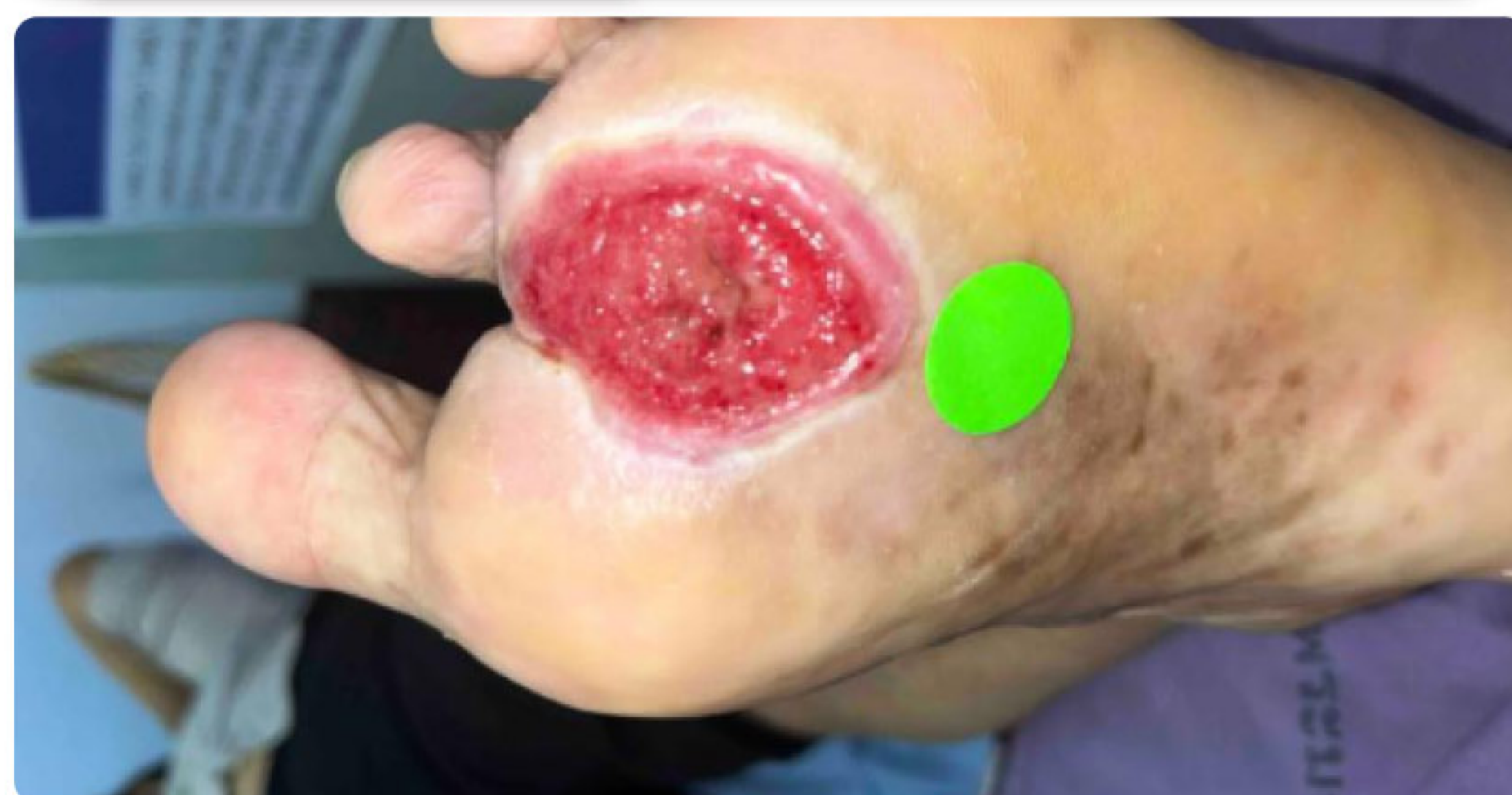PROGRESS



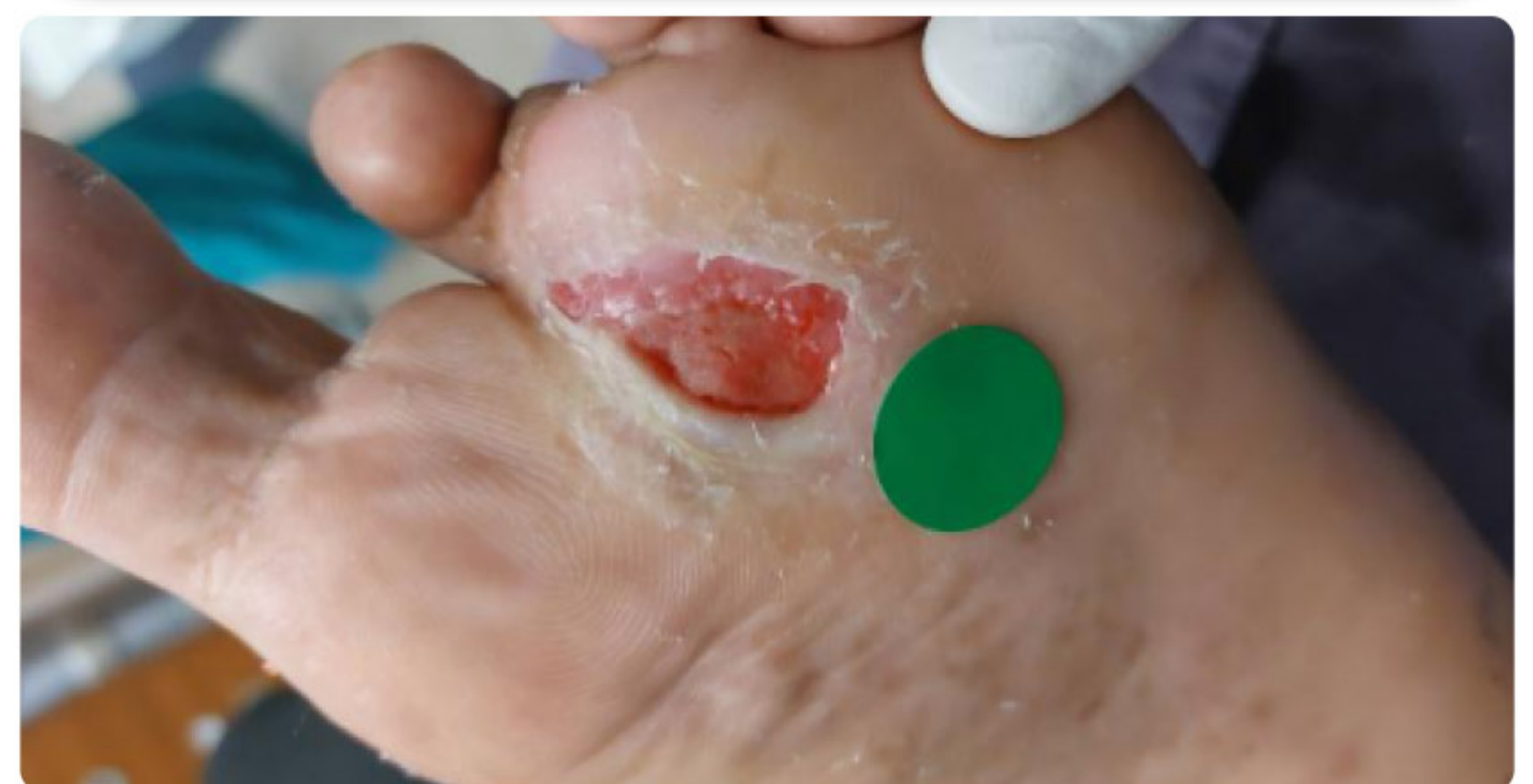A Figure A: At presentation



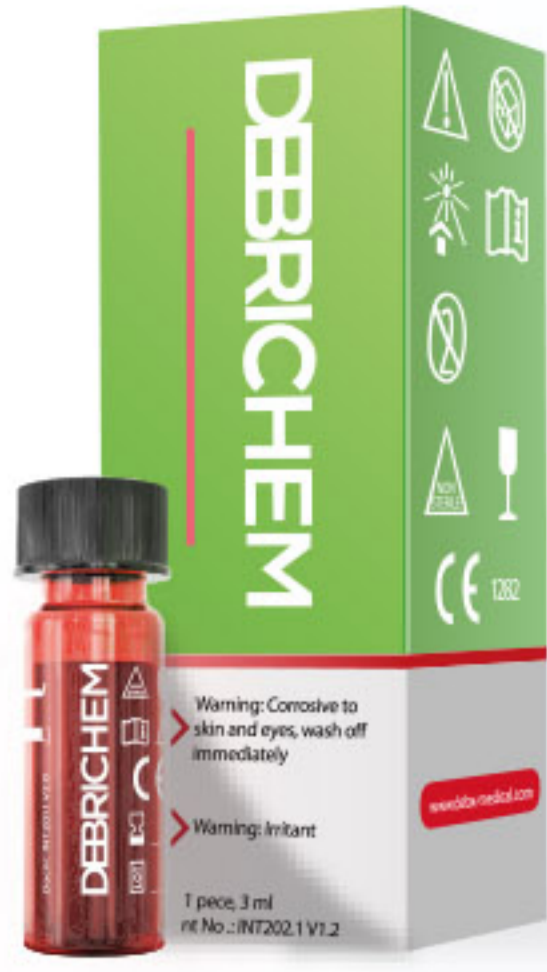B Figure B: 1 week post DEBRICHEM



C Figure C: 2 months post DEBRICHEM



D Figure D: 4 months post second application



CASE 46

63- YEAR-OLD MALE WITH RIGHT FOOT
DIABETIC ULCER

AUTHOR

S. AMESZ, DEVENTER ZIEKENHUIS,
NETHERLANDS

ETIOLOGY

DIABETIC FOOT ULCER



GENERAL MEDICAL HISTORY

- ✓ Diabetes Mellites
- ✓ Obesity
- ✓ Returning ulcerations
- ✓ Hypercholesteremia
- ✓ Left ventricular dysfunction
- ✓ Renal insufficiency
- ✓ Respiratory insufficiency
- ✓ Vascular insufficiency
- ✓ Heart failure

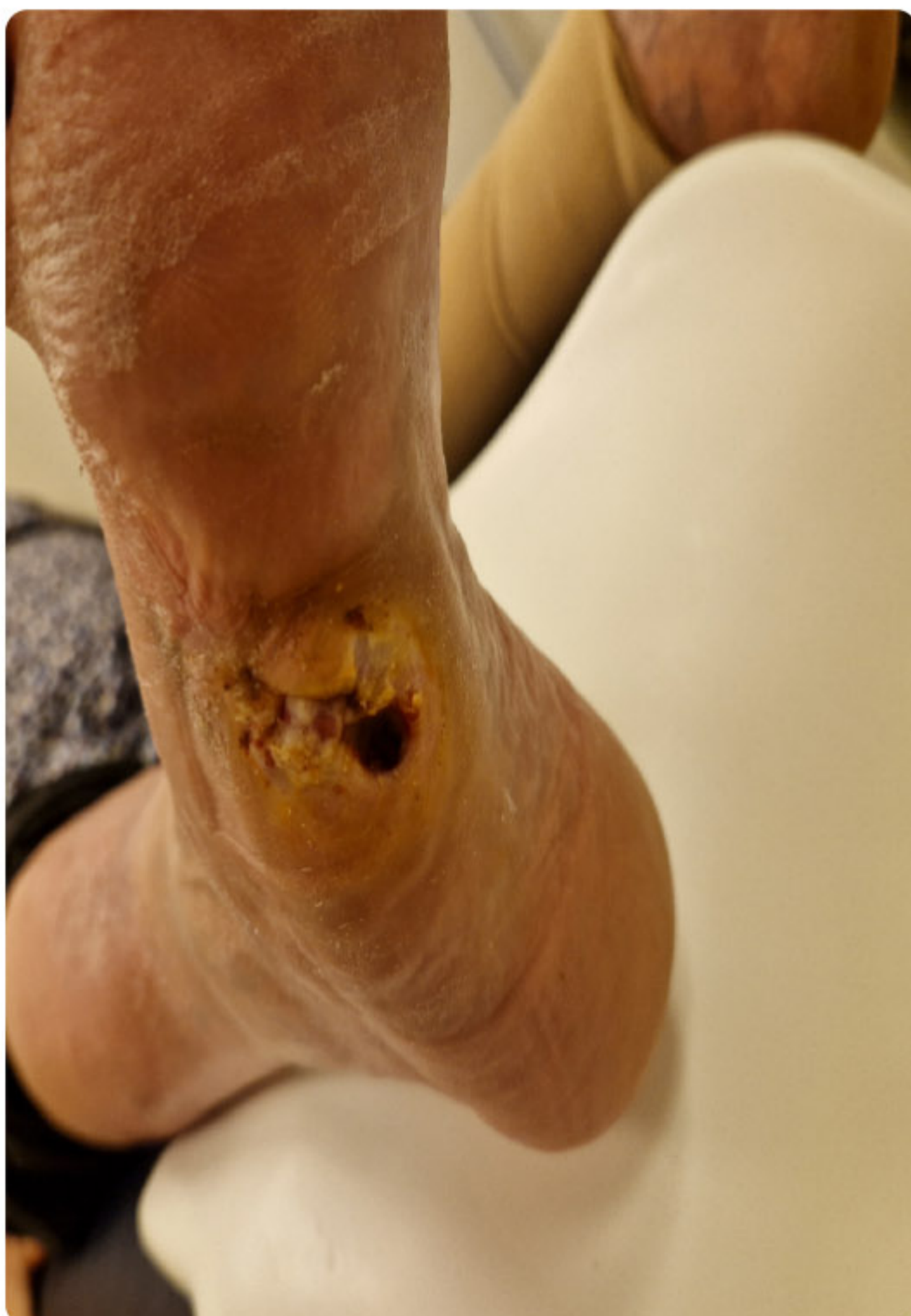DESCRIPTION

The 63-year-old male patient presented with a neuro-ischemic diabetic foot ulcer (Figure A), which had been persistent for 14 weeks. The ulcer was localized on the right foot. Prior to the current treatment, the patient had undergone offloading measures along with the application of antimicrobial dressings. Over the initial three-week period following the commencement of treatment, there was an unexpected increase in the size of the wound (Figure B).

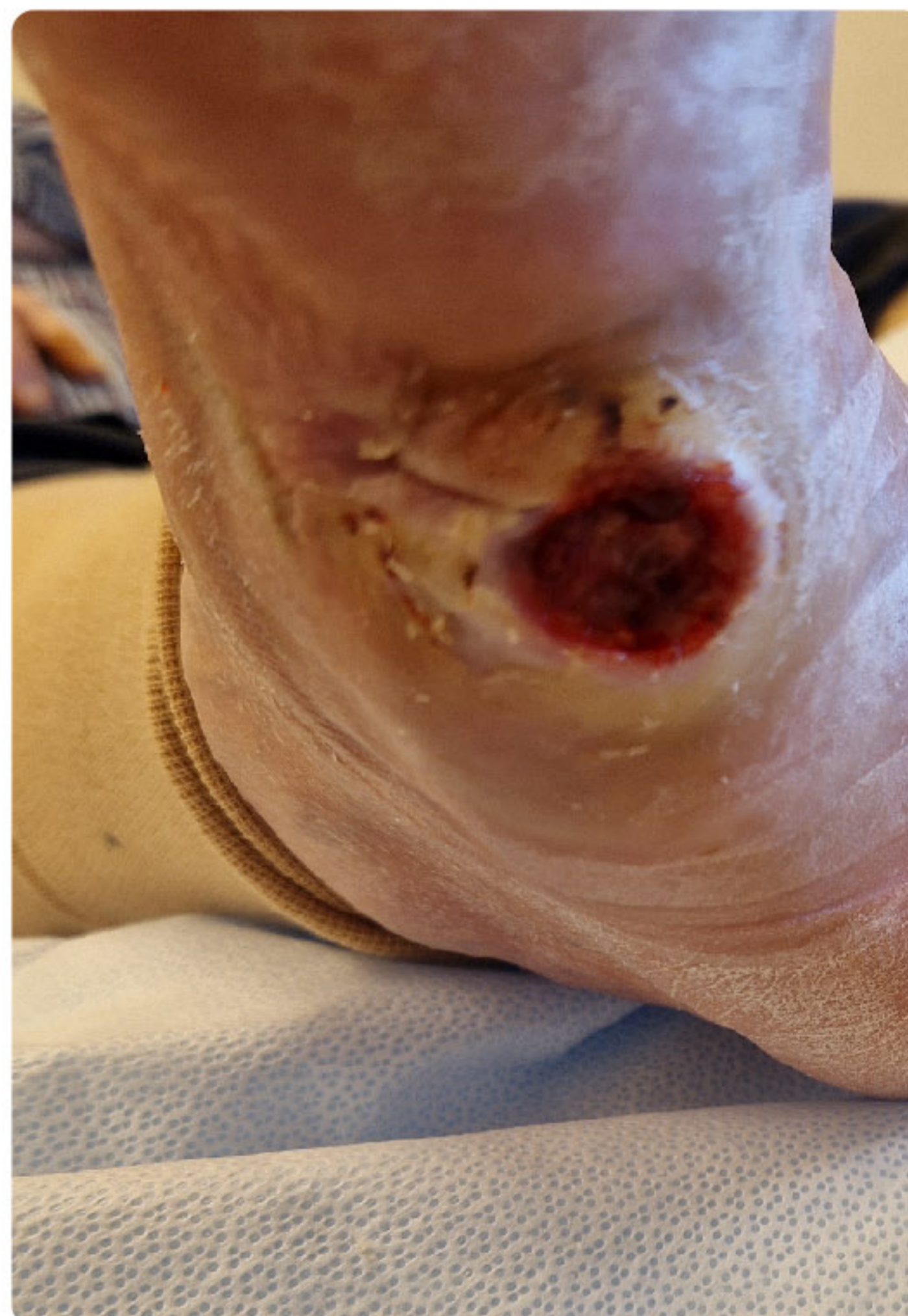The patient underwent further offloading measures, along with the utilization of antimicrobial dressings. These interventions were augmented by additional therapeutic modalities aimed at facilitating wound healing.

After a total treatment duration of 14 weeks, the wound achieved complete healing (Figure C).

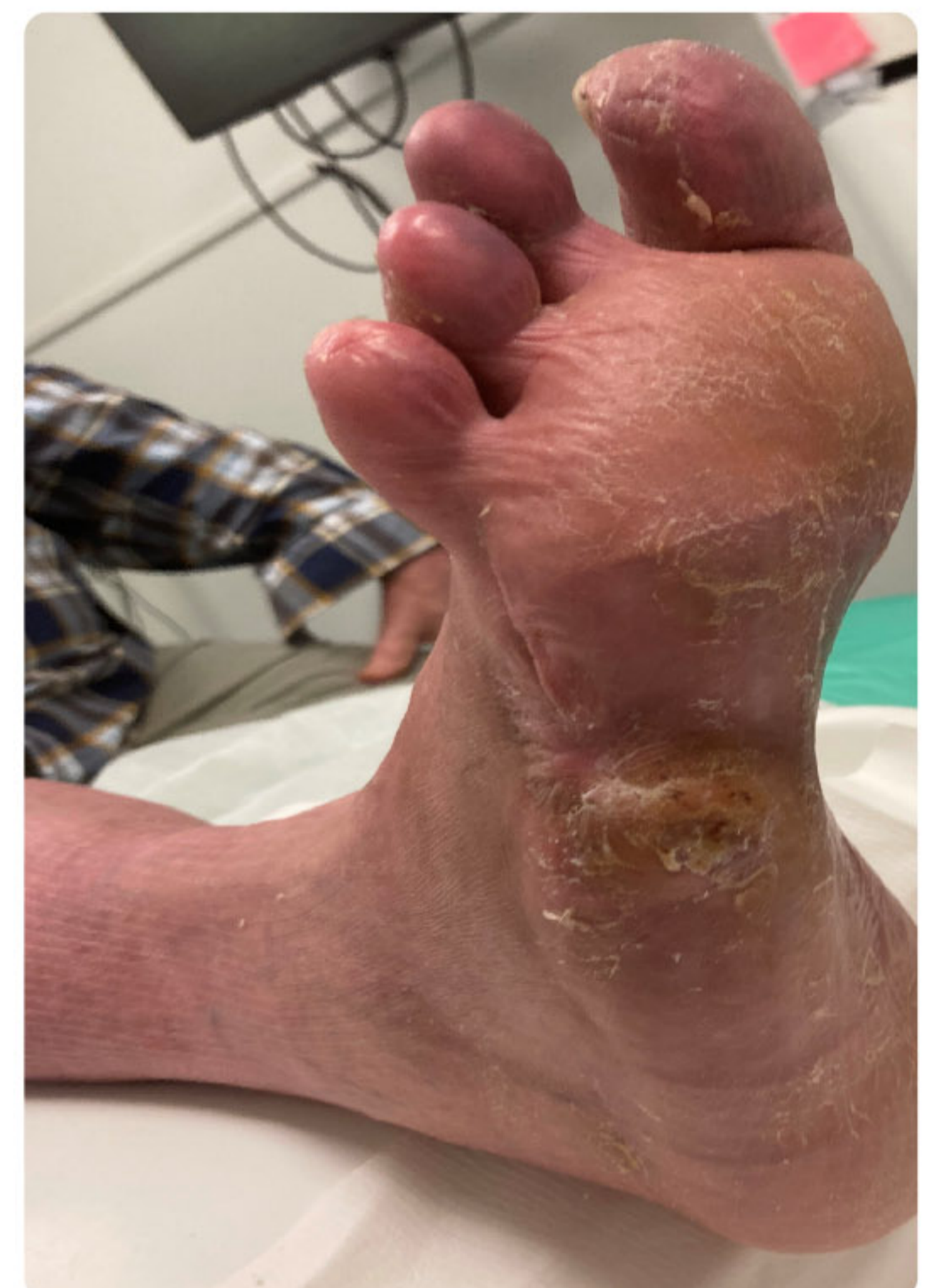PROGRESS



1. Figure A: At presentation



2. Figure B: At 3 weeks post DEBRICHEM



3. Figure C: 14 weeks after DEBRICHEM



CASE 47

83- YEAR-OLD MALE WITH
A DIABETIC FOOT ULCER ON LEFT FOOT

AUTHOR

S. AMESZ, DEVENTER ZIEKENHUIS,
NETHERLANDS

ETIOLOGY

DIABETIC FOOT ULCER



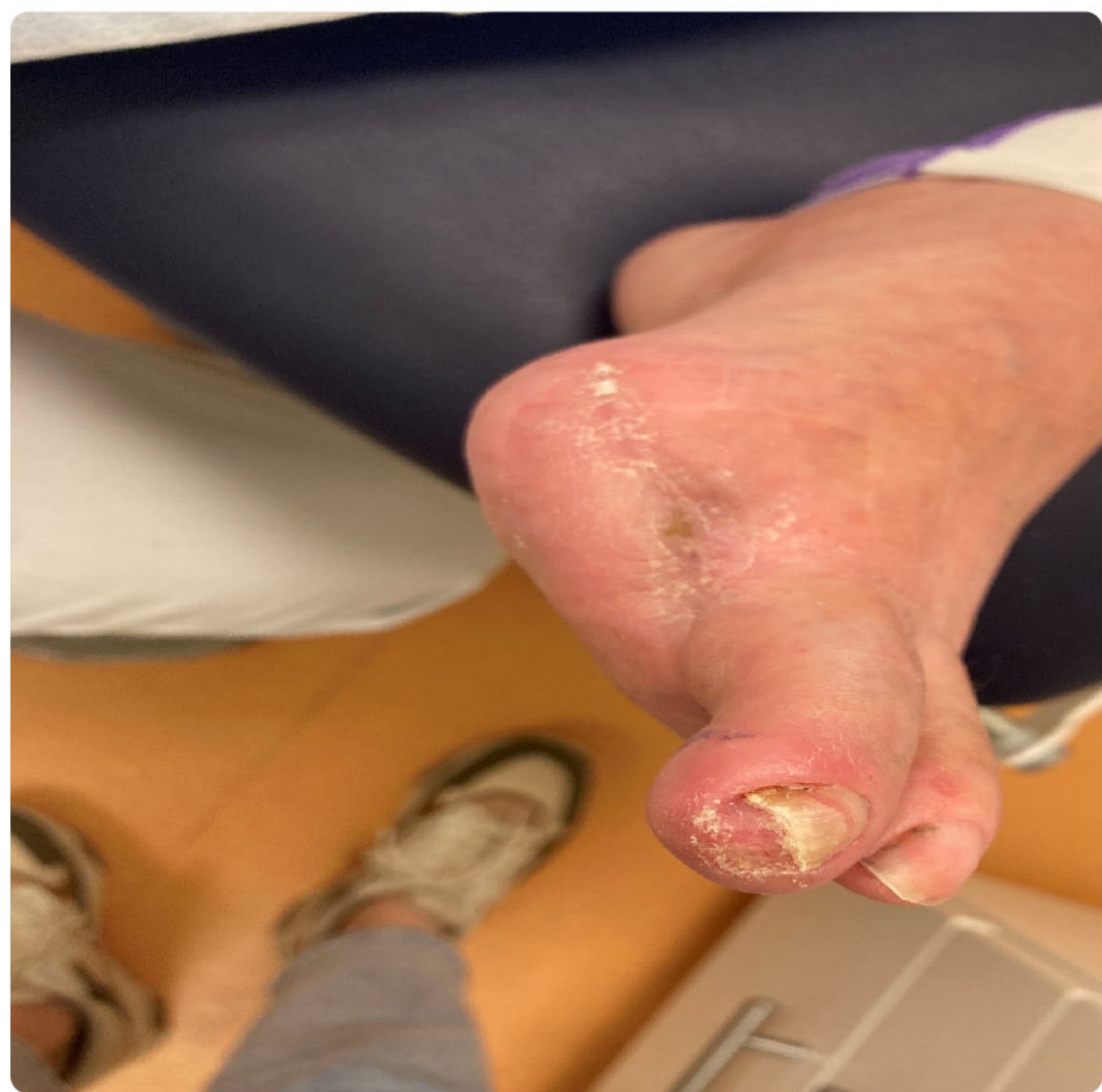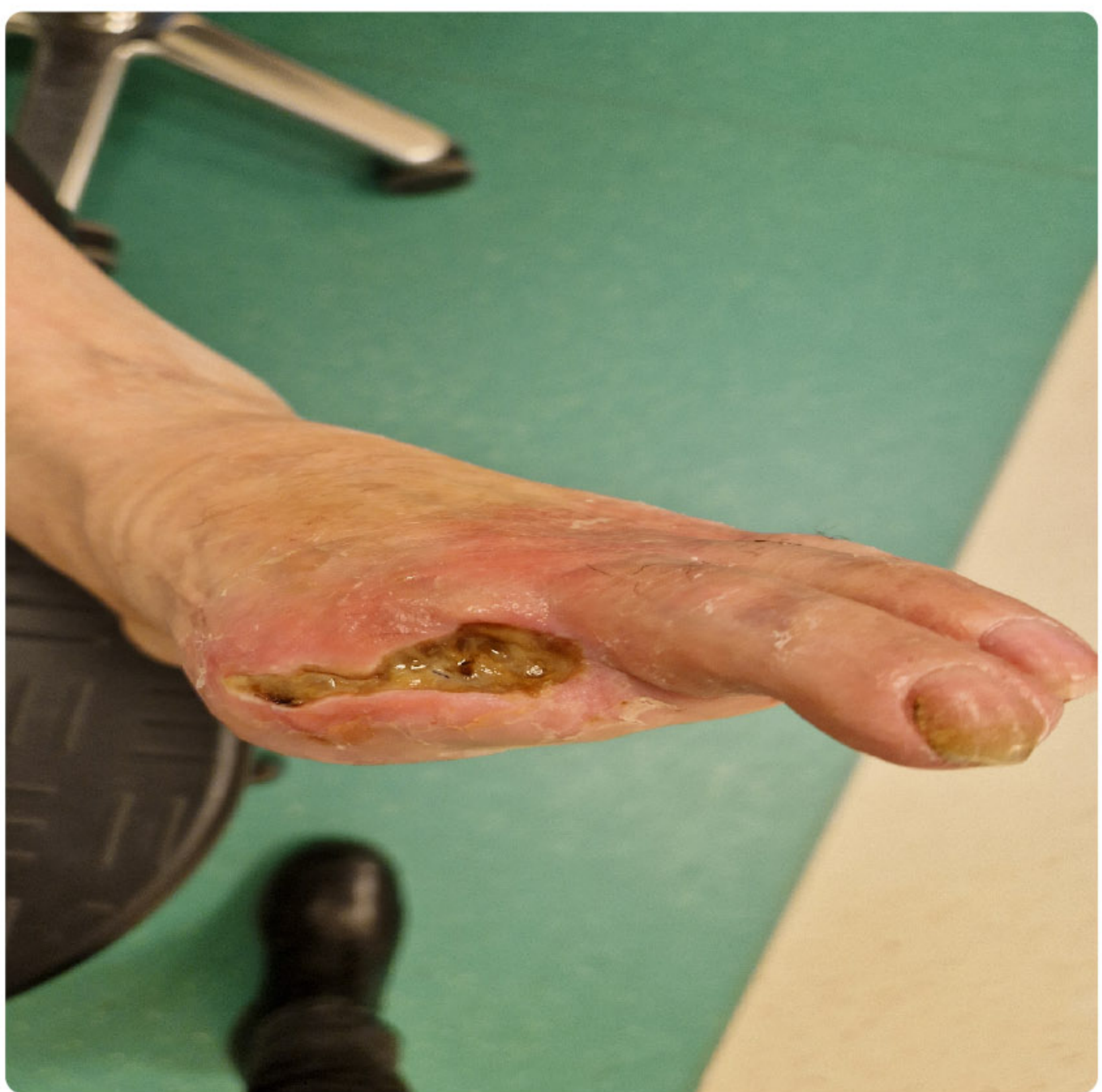DEB^x MEDICAL GENERAL MEDICAL HISTORY

- ✓ Diabetes Melitus
- ✓ Hypertension
- ✓ Gout
- ✓ Periferal arterial disease
- ✓ Hallux amputation

DEB^x MEDICAL DESCRIPTION

The 83-year-old male patient presented with a longstanding neuro-ischemic diabetic foot ulcer, which had been persistent for 21 weeks (Figure A). The ulcer was situated on the left foot, with the first digit previously amputated. Preceding the current treatment, the patient had received care involving the application of antimicrobial dressings and compression therapy. Following DEBRICHEM treatment, notable progress was observed within the first week. The wound exhibited a marked improvement in clarity, suggesting a positive response. Follow-up treatment consists of antimicrobial dressing application and compression therapy. Over the subsequent weeks, the wound continued to demonstrate favorable signs of healing, with after a total treatment duration of 12 weeks, the wound achieved complete healing (Figure B).

DEB^x MEDICAL PROGRESS



A. Figure A: At presentation

B. Figure B: 12 weeks after DEBRICHEM



CASE 25

56- YEAR-OLD MALE WITH
PRESSURE ULCER ON THE SACRAL AREA

AUTHOR

C. ROUGIER, CHU BORDEAUX, FRANCE

ETIOLOGY

PRESSURE ULCER



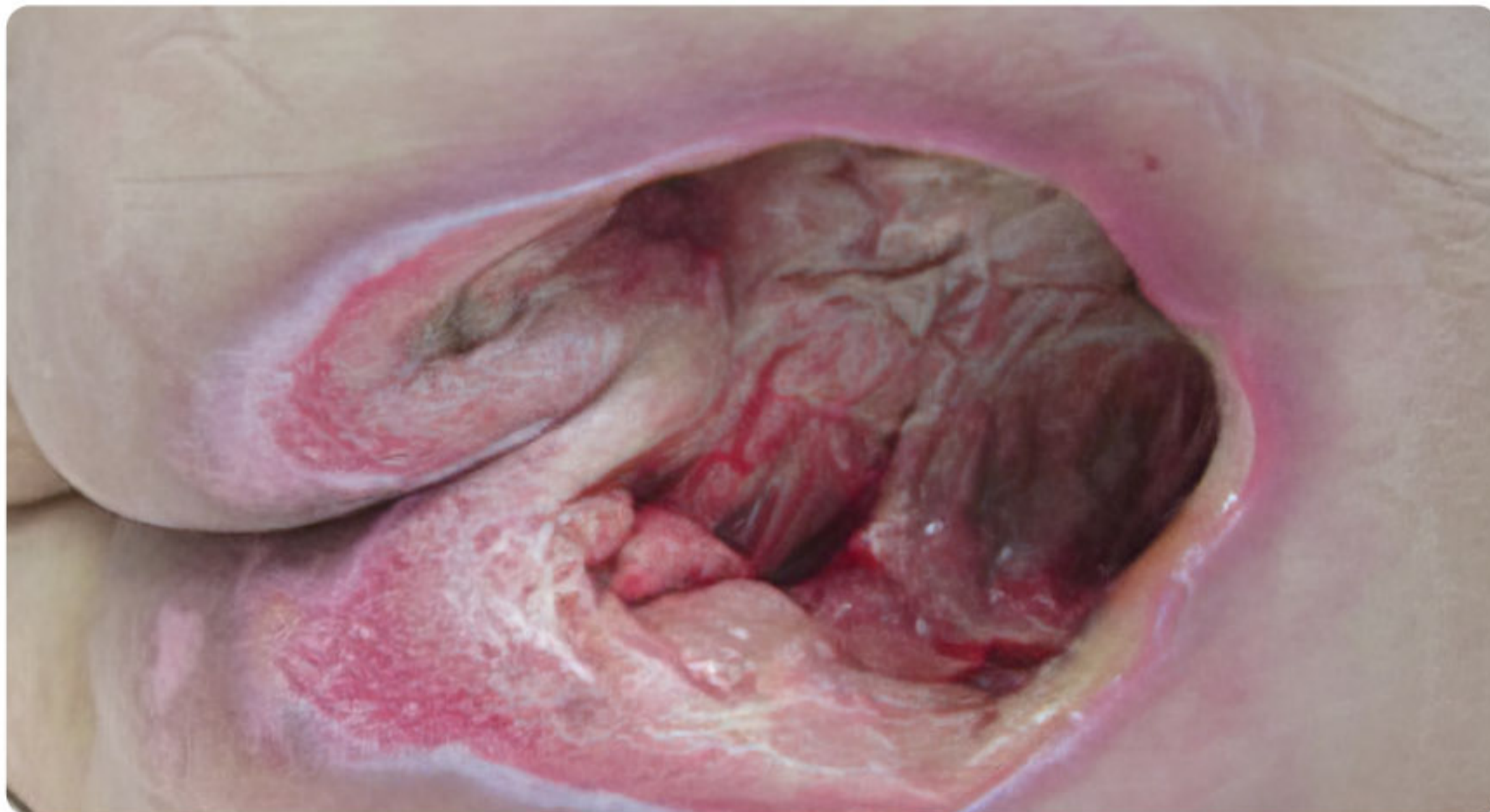GENERAL MEDICAL HISTORY

- ✓ Diabetes Mellitus
- ✓ Cardiogenic shock

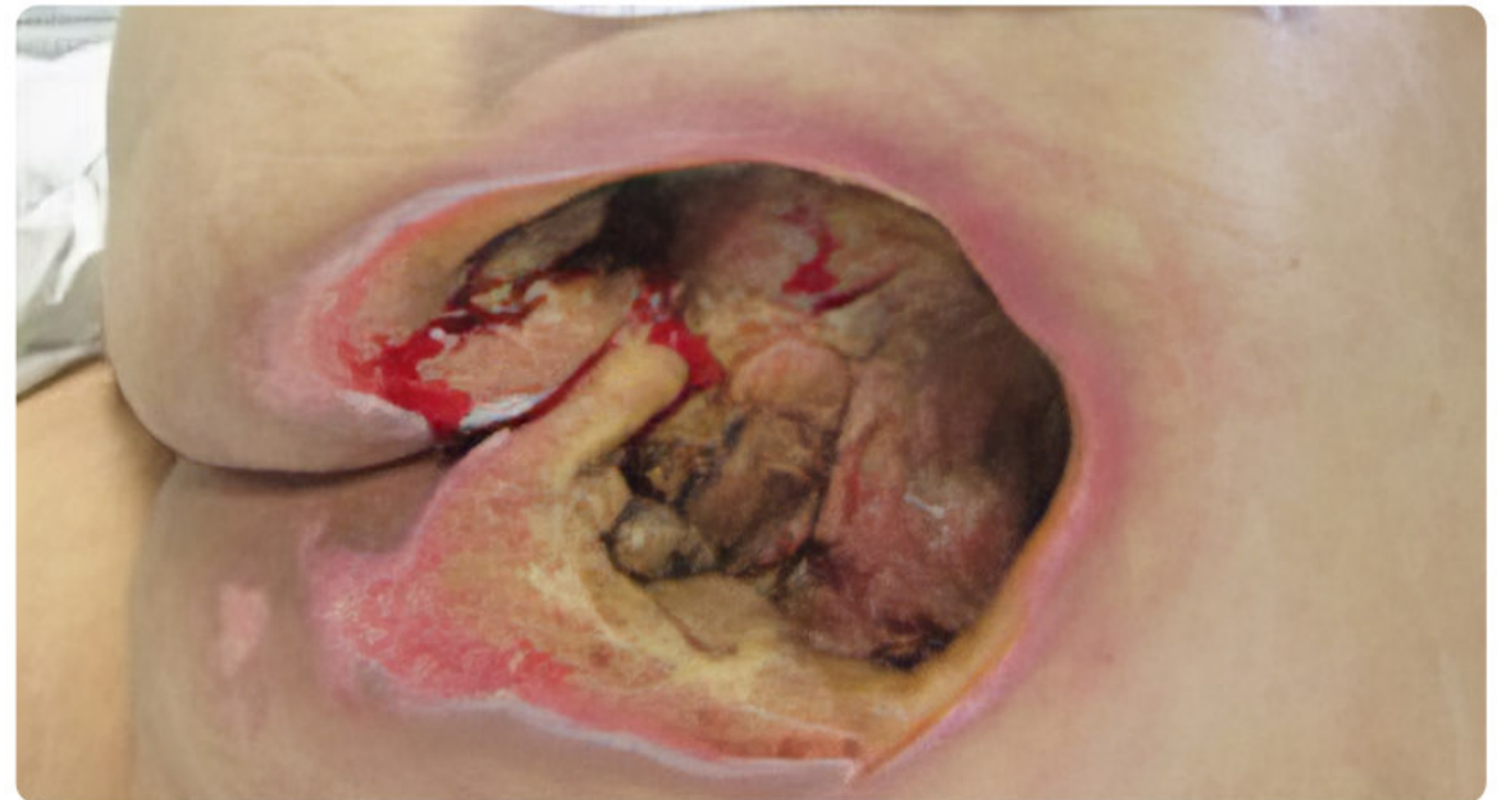
DESCRIPTION

The patient entered the clinic with a cardiogenic shock. A transient assistance of blood perfusion at the aortic level was installed via a surgical procedure. At the ICU a pressure ulcer(PU) developed. After 1,5 months the necrosis was trimmed and NWPT was started. 2 Weeks later the PU was debrided with DEBRICHEM under full sedation. Figure A shows the ulcer prior to DEBRICHEM treatment: it is deep, covered in slough and measures 11 x 8cmx 2,5 cm deep) Post-DEBRICHEM treatment significant change was observed. (Figure B) Two months post-DEBRICHEM treatment the wound bed shows full granulation(Figure C). 3 Months post- DEBRICHEM significant epithelialization with a strong reduction in depth and size is observed (4x 4cm and 0,5 cm deep) (Figure D). Follow-up care for post-DEBRICHEM was set at a biweekly dressing changes and nutritional supplements.

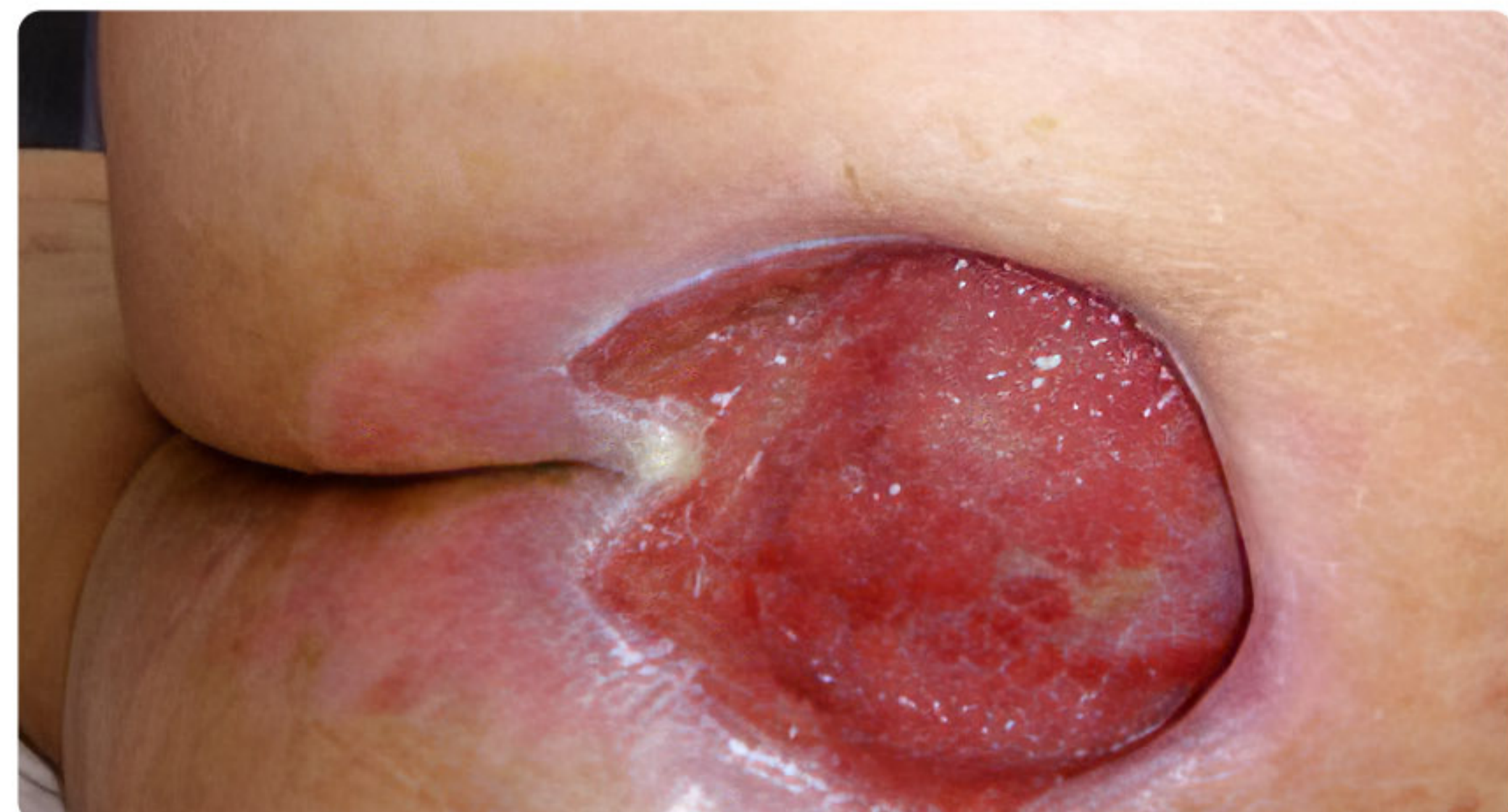PROGRESS



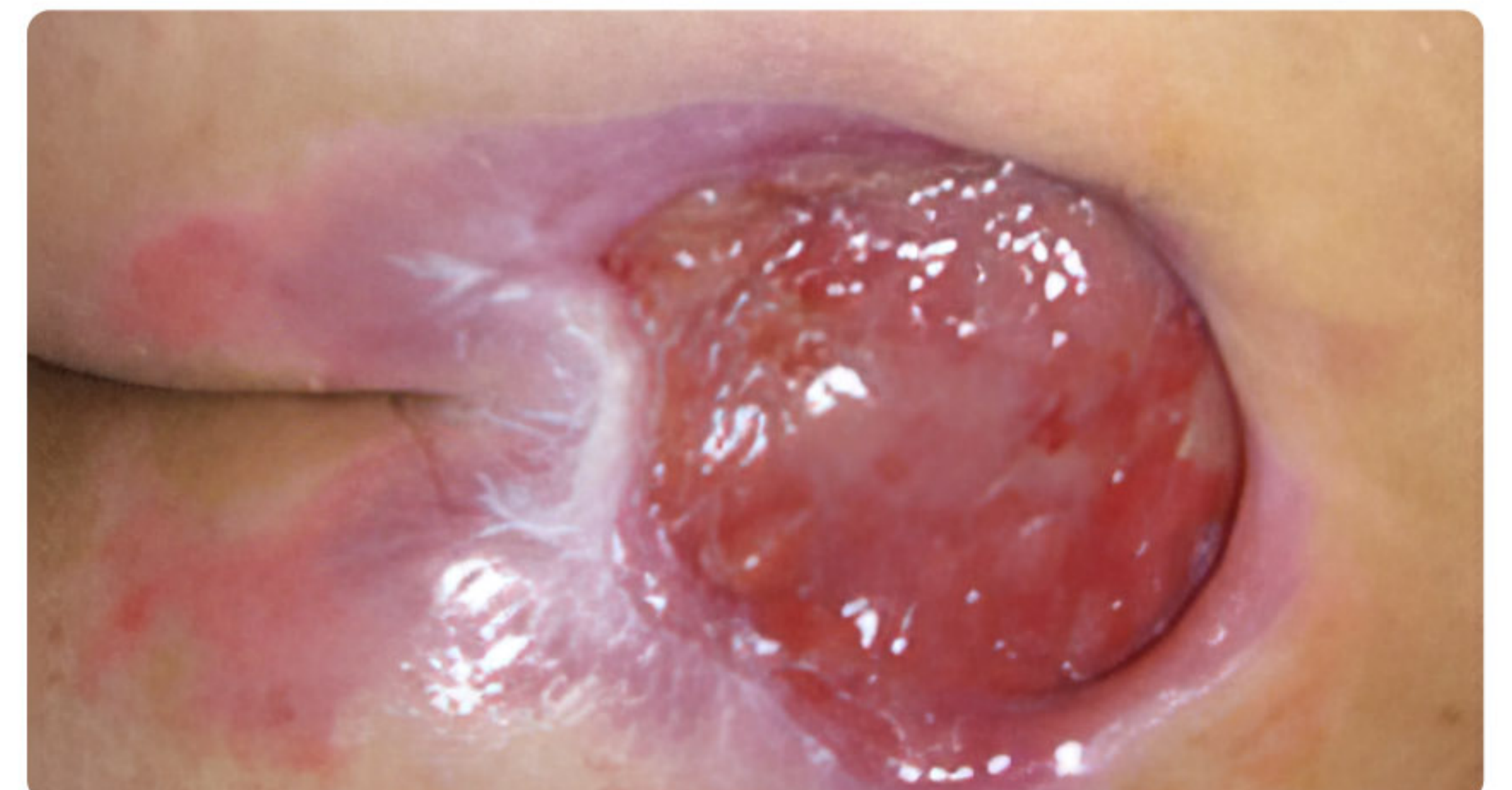1. Figure A: Wound presented a clinic



2. Figure B: Immediately after DEBRICHEM treatment



3. Figure C: 2 months after DEBRICHEM



4. Figure D: 3 months after DEBRICHEM



CASE 34

82- YEAR-OLD FEMALE WITH A
PRESSURE ULCER ON LEFT HEEL

AUTHOR

M.A. MELADO,
HERIDEA ENFERMERIA AVANZADA, SPAIN

ETIOLOGY

PRESSURE ULCER



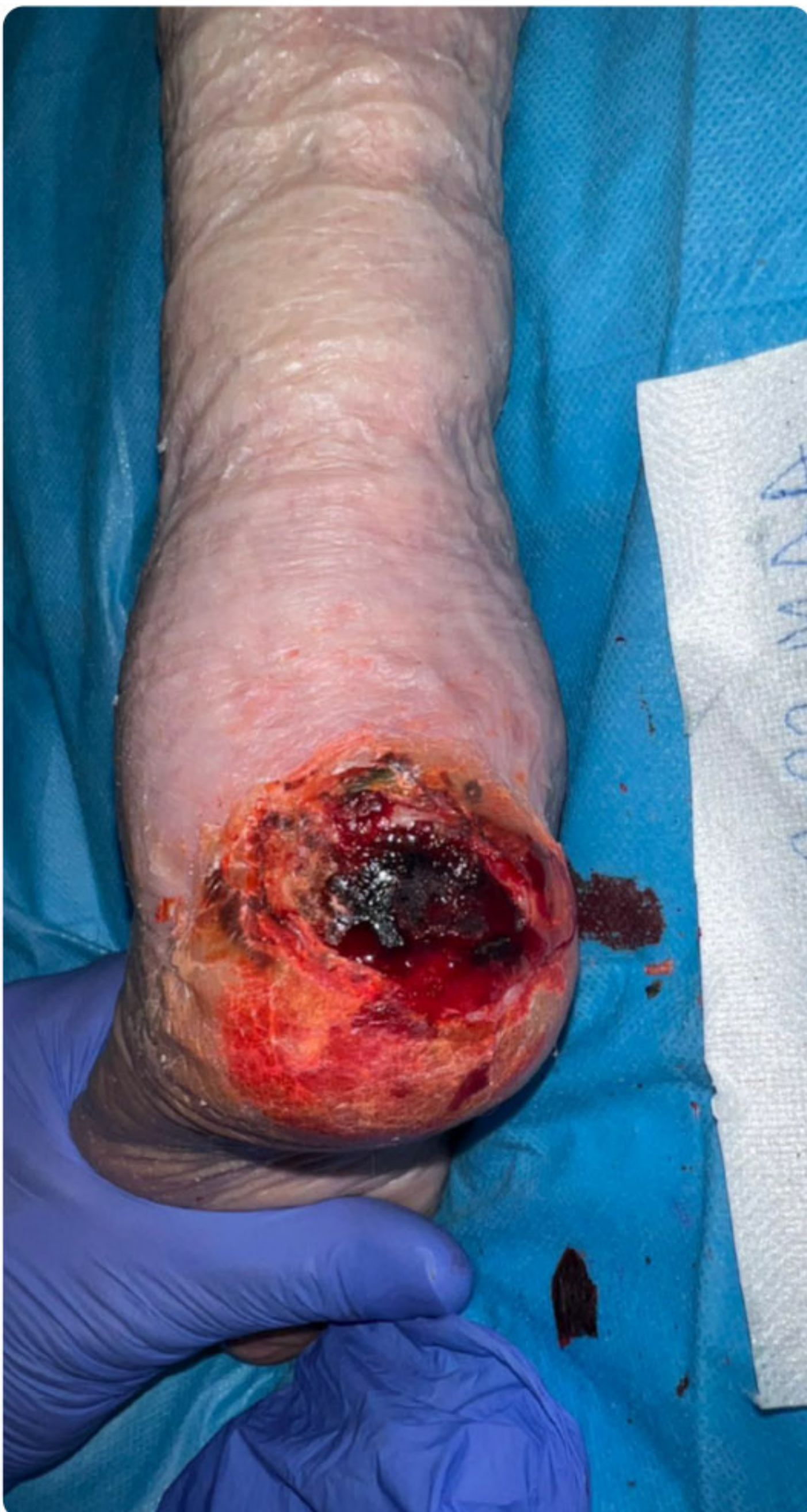GENERAL MEDICAL HISTORY

- ✓ Hypertension
- ✓ Diabetes Mellitus
- ✓ Chronic renal failure
- ✓ Hyperuricemia

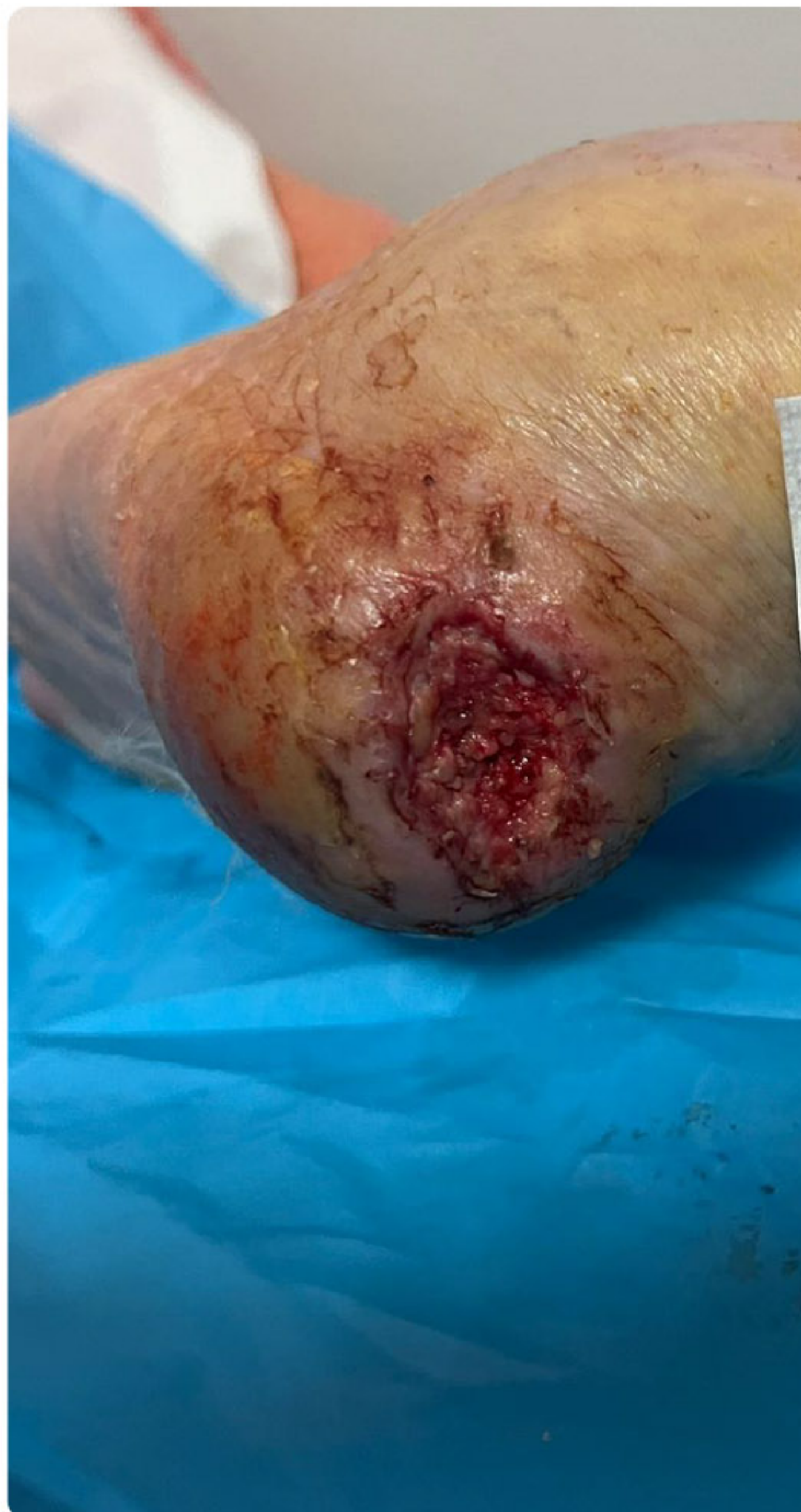DESCRIPTION

Patient with history of hypertension, diabetes mellitus, chronic renal failure, and hyperuricemia presented with a pressure ulcer on the left heel that had been present for seven months. The wound was previously treated with collagenase and Manuka honey, but showed minimal improvement (Figure A). DEBRICHEM was applied to the wound, and followed by a curettage of the desiccated material within 15 minutes after the application. The treatment was continued with biweekly dressing changes, and offloading. At the 1-week follow-up visit, the wound had good granulation tissue formation (Figure B). Complete healing of the wound was achieved after 3 weeks and the patient was advised to continue with appropriate pressure relief measures to prevent further ulcer formation (Figure C).

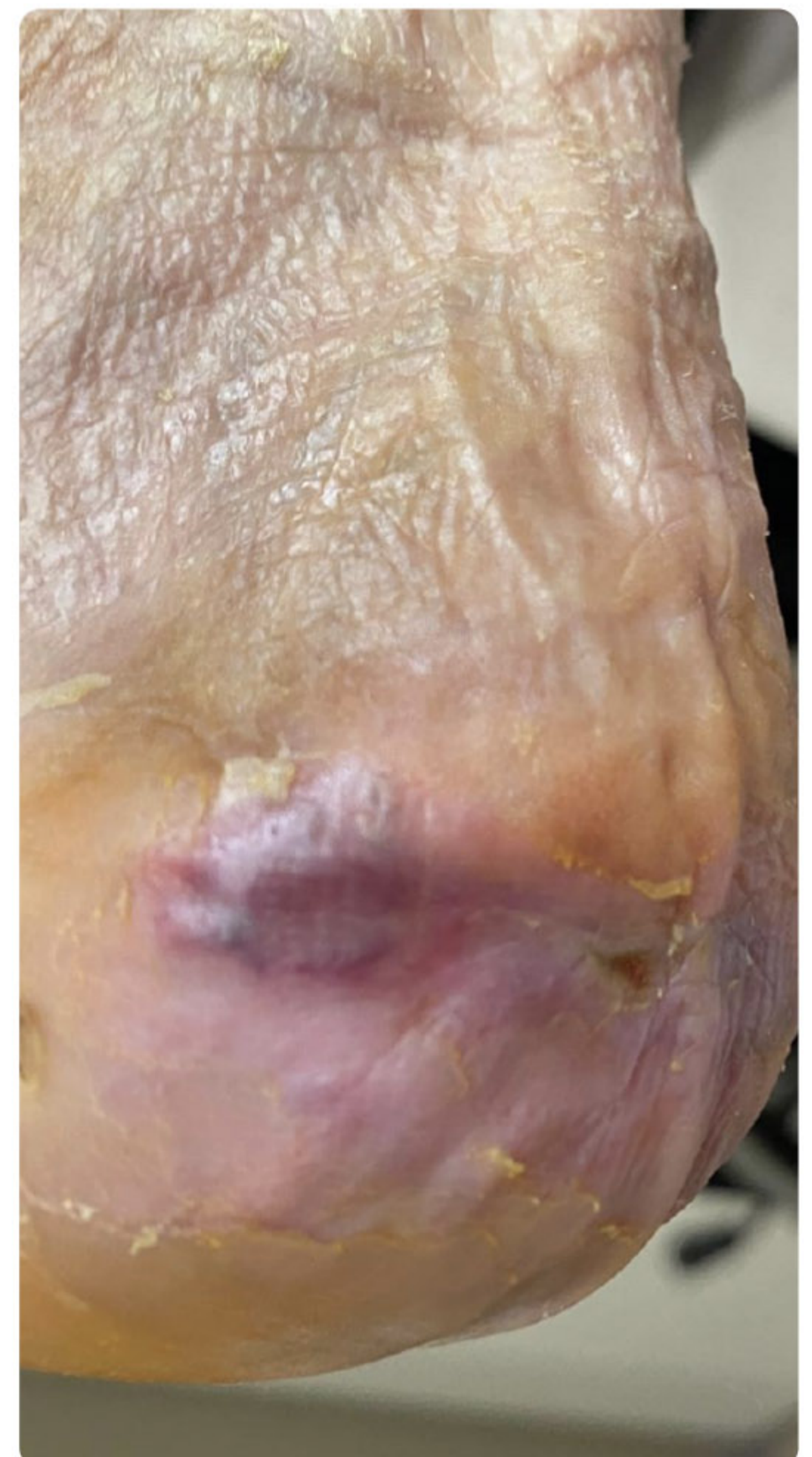
PROGRESS



1. Figure A: Wound presented prior to DEBRICHEM application



2. Figure B: Wound 1 week Post-DEBRICHEM application



3. Figure C: Wound 1.5 months Post-DEBRICHEM application



CASE 38

85- YEAR-OLD FEMALE WITH
WITH TWO PRESSURE INJURIES

AUTHOR

J. FIDALGO, ZARAGOSZA
GENERAL HOSPITAL, SPAIN

ETIOLOGY

VASCULITIC ULCER



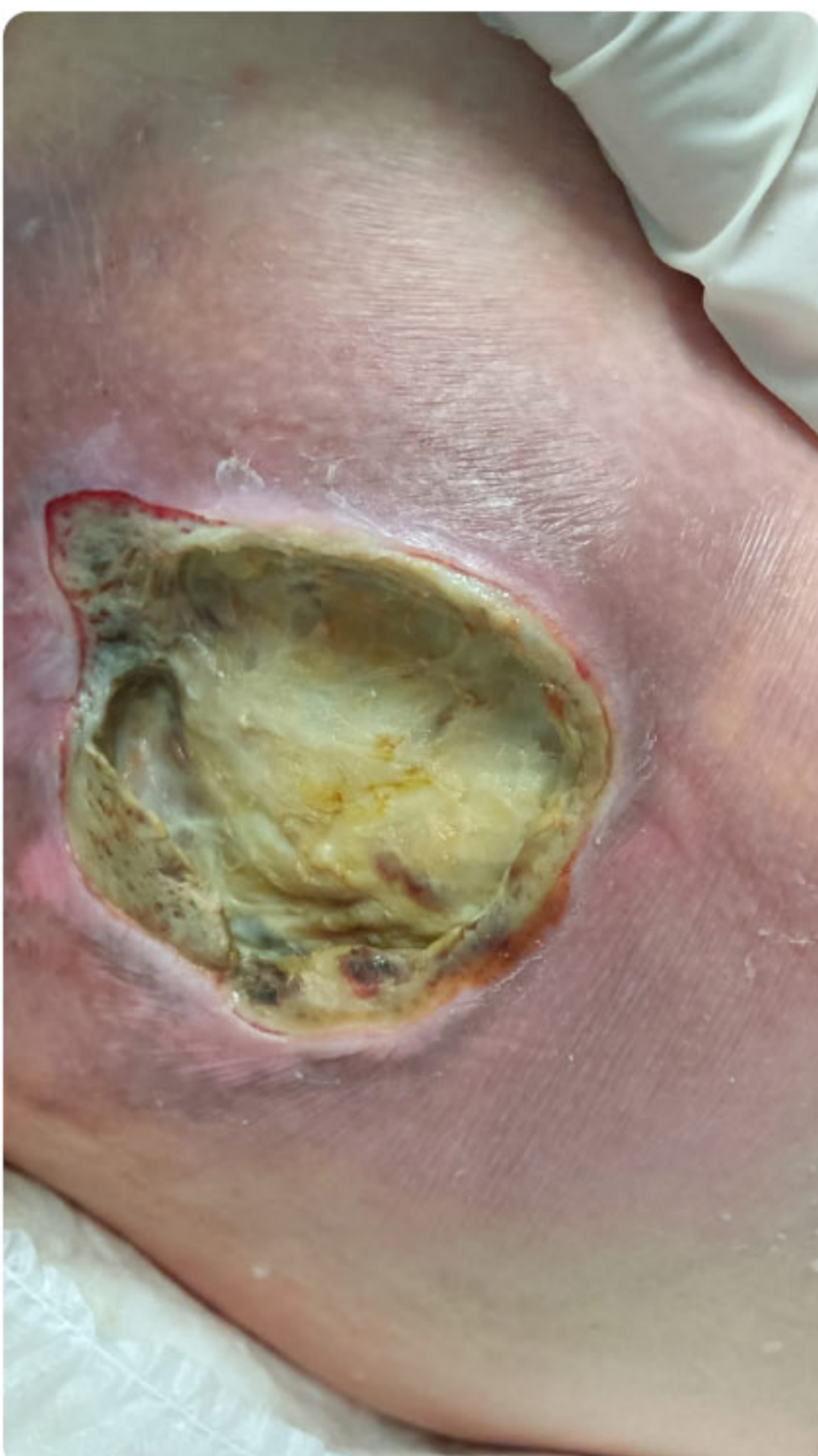
GENERAL MEDICAL HISTORY

- ✓ Hypertension
- ✓ Dyslipidaemia
- ✓ Diabetes mellitus
- ✓ Alzheimer's disease
- ✓ Hyperuricaemia
- ✓ Paget's disease
- ✓ Gonarthrosis
- ✓ SARS-CoV2 infection with pneumonia
- ✓ Haematoma

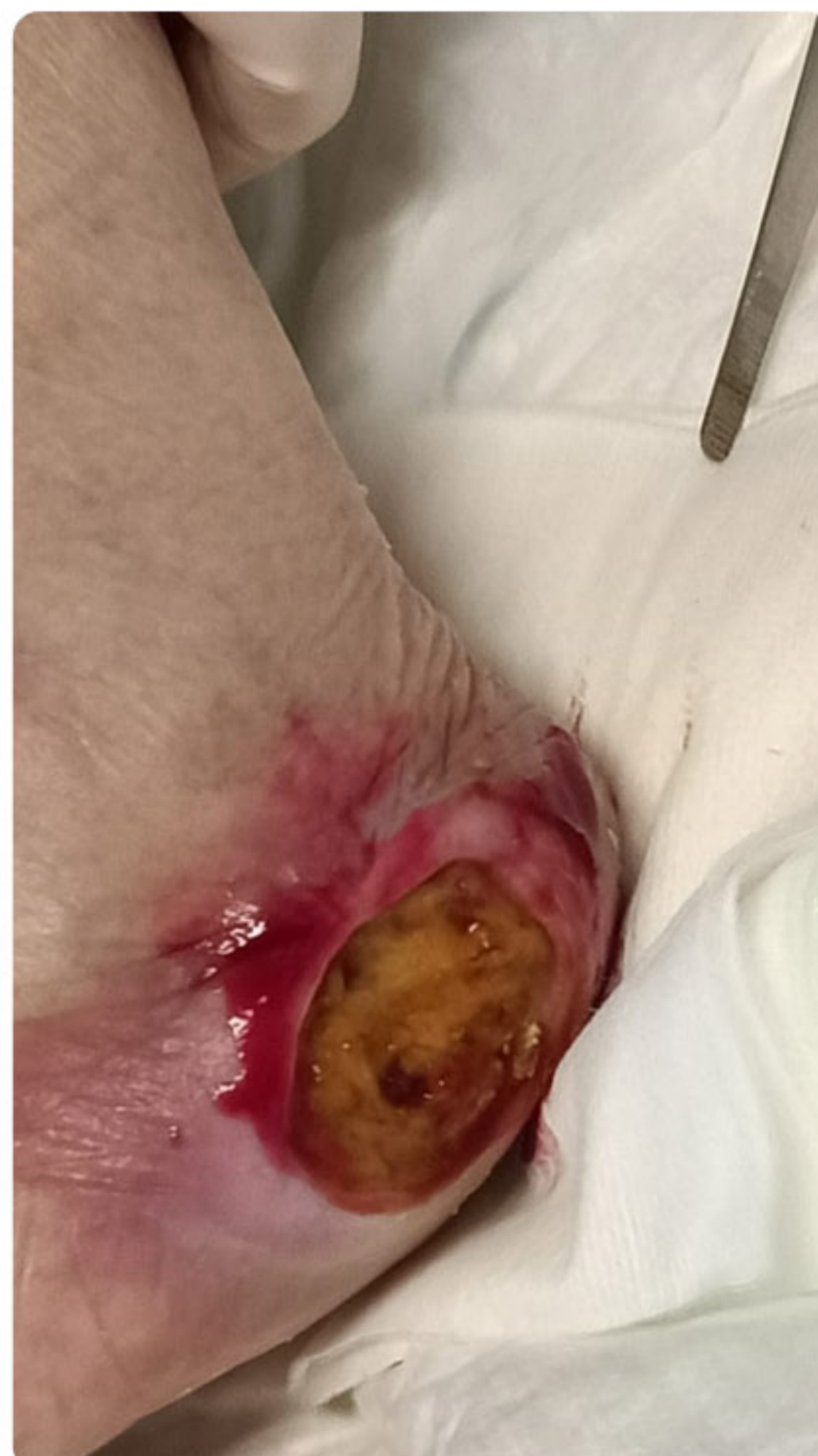DESCRIPTION

The patient presented with a complex medical history, including cognitive impairment, arterial hypertension, dyslipidaemia, diabetes mellitus, Alzheimer's disease,, hyperuricaemia, Paget's disease, gonarthrosis, SARS-CoV2 infection, pneumonia, haematoma and two pressure ulcers that had been present for 4 months. The ulcers were located in the sacral and heel area. Both wounds were infected by Pseudomonas sp. and had heavy and moderate exudate respectively, and were painful with a VAS of 6 and 7 respectively (Figure A1 and A2). Prior to DEBRICHEM application, lidocaine spray and topical procaine were applied locally, and the wounds were covered with a film for 30 minutes. Follow-up treatment consisted of moist environment dressings, changed three times per week. In 2 weeks, almost 100% of the wound bed surface showed granulation tissue (Figures B1 and B2). Due to the patient's poor state of health and bronchial aspiration, the patient expired a month and a half later and was lost to follow-up.

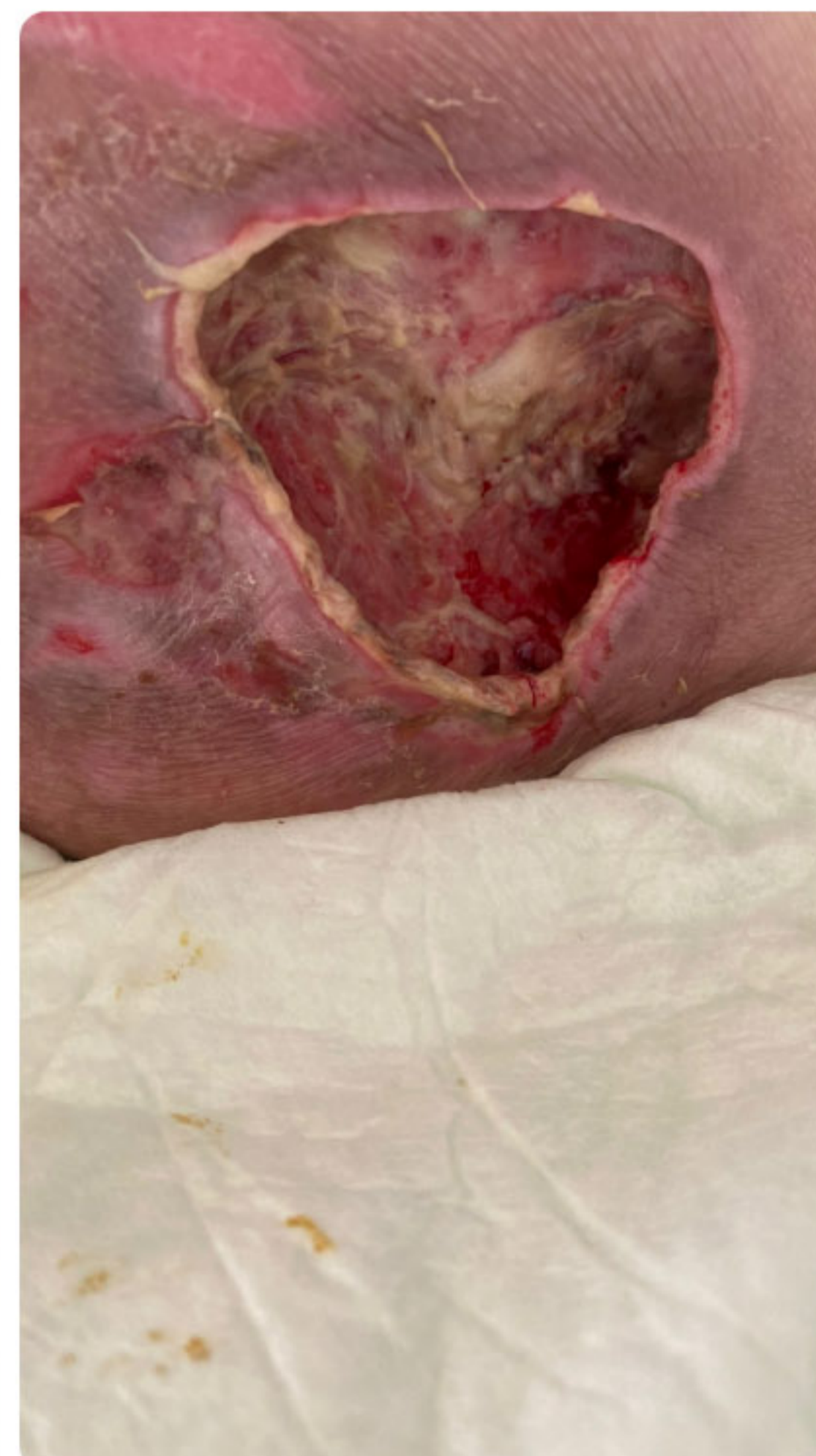PROGRESS



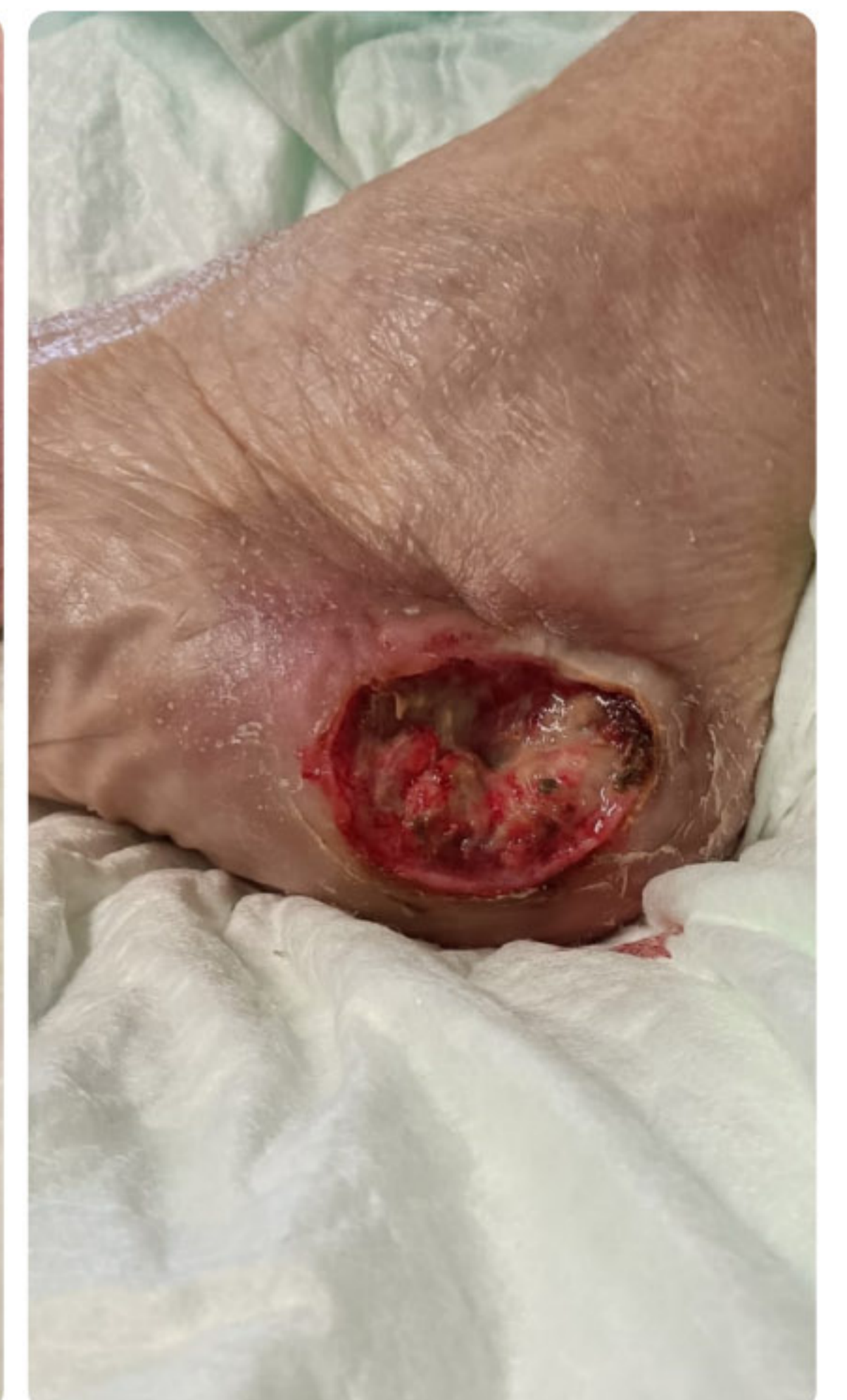A1 Figure A1: Wound presented prior to DEBRICHEM application



A2 Figure A2: Wound presented prior to DEBRICHEM application



B1 Figure B1: Wound 2 weeks Post-DEBRICHEM application



B2 Figure B2: Wound 2 weeks Post-DEBRICHEM application



CASE 41

67- YEAR-OLD MALE WITH
A PRESSURE ULCER ON LEFT HIP

AUTHOR

PHRAMONGKUTKLAO HOSPITAL, THAILAND

ETIOLOGY

PRESSURE ULCER



GENERAL MEDICAL HISTORY

- ✓ Hypertension
- ✓ Spinal cord injury

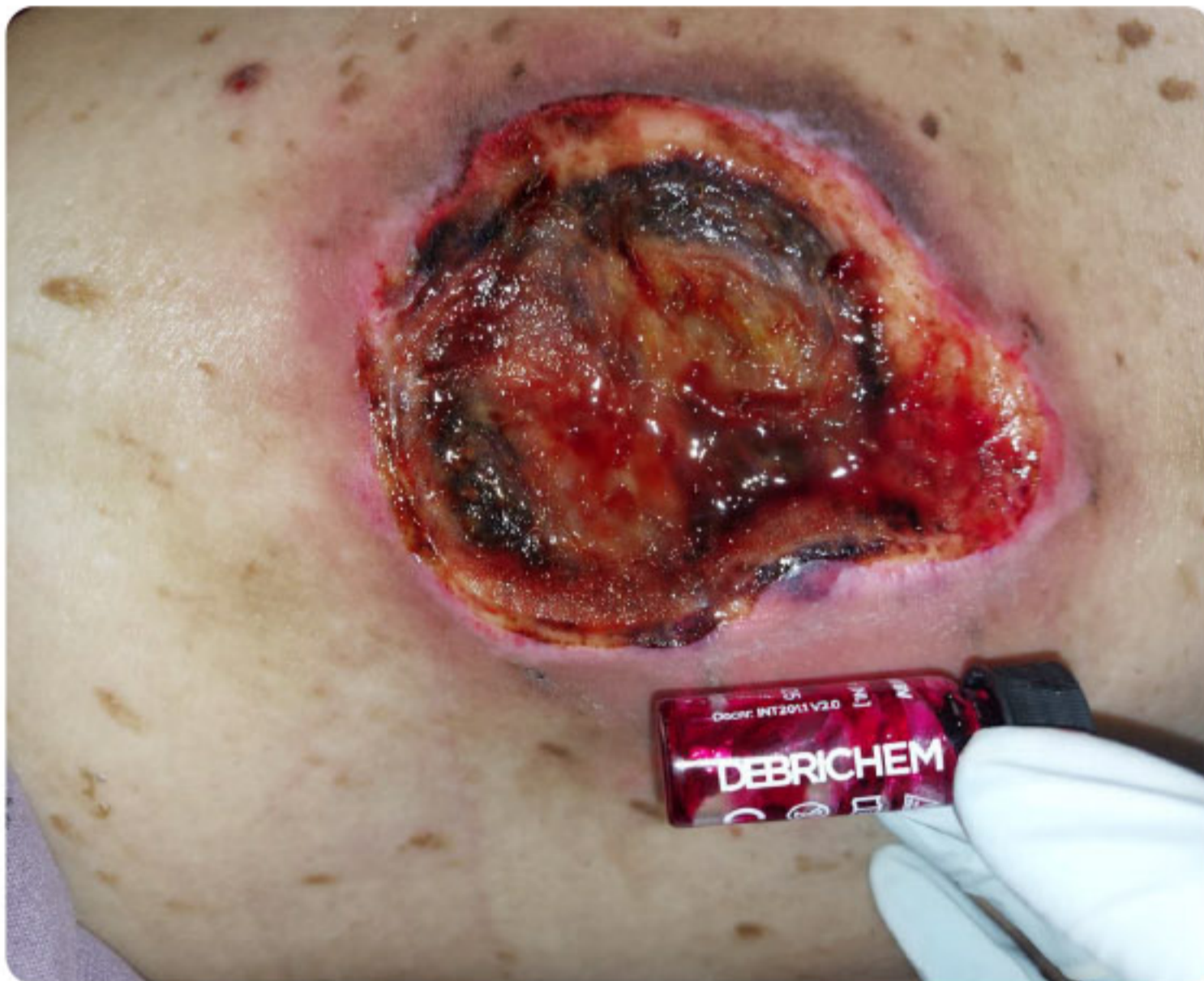

DESCRIPTION

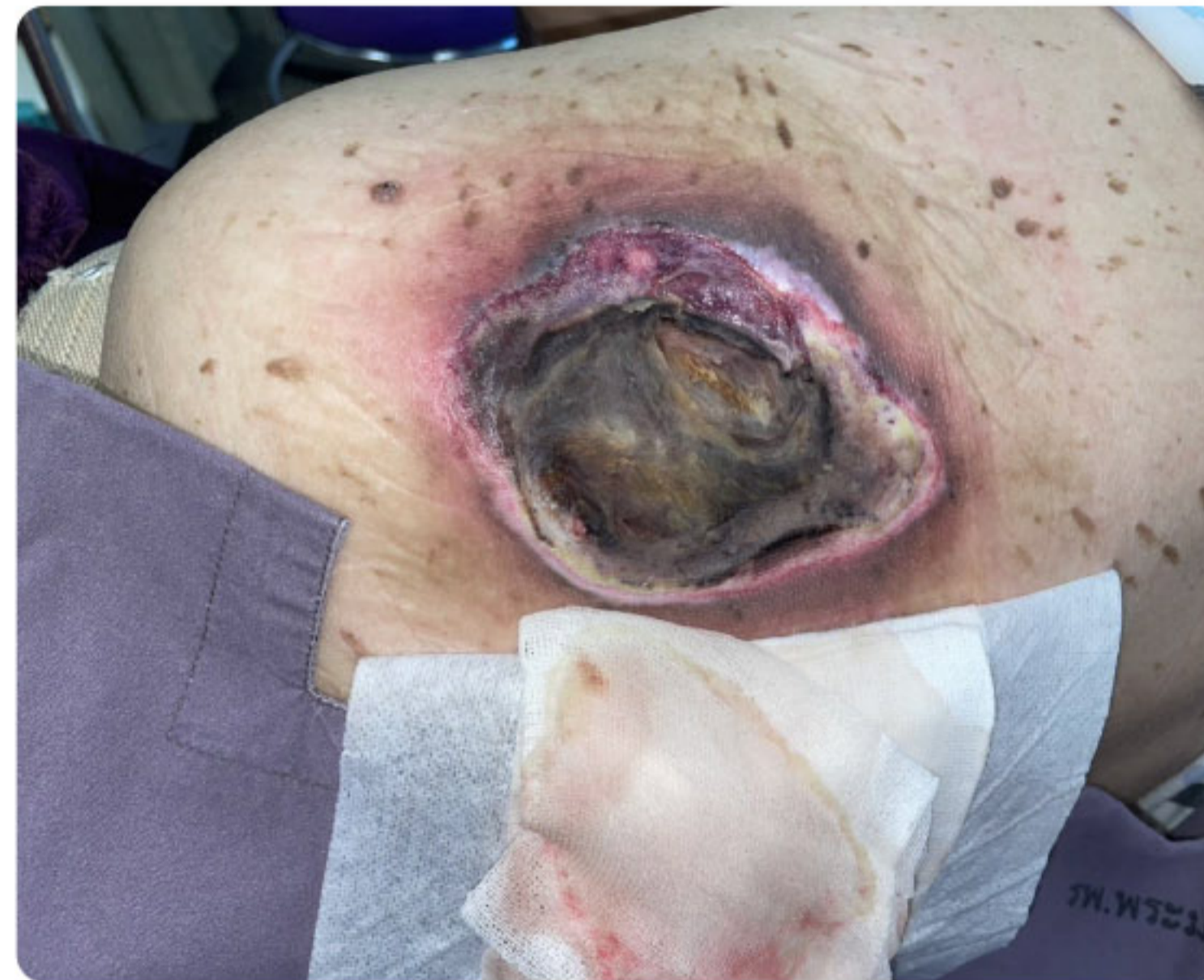A 67-year-old male with a history of spinal cord injury and hypertension presented with a pressure ulcer on the left hip. The ulcer was treated with DEBRICHEM. Multiple bacteria were identified in the ulcer, among which: *Proteus mirabilis*, *Enterococcus faecalis*, *Pseudomonas aeruginosa* (Figure A). Initial treatment with DEBRICHEM resulted in significant improvement of the pressure ulcer and reduction of the infection (figure B). However, after 3 weeks post-application, another infection was suspected (Figure C). A second DEBRICHEM debridement was chosen as treatment (figure D). Following the second DEBRICHEM debridement, the wound showed positive progress. Three months after the second treatment, full granulation and onset of epithelialization were observed, indicating successful wound healing progression (Figure E). During follow-up Treatment, standard of care was performed with dressings to control the right moisture balance to maintain optimal wound environment and facilitate healing.



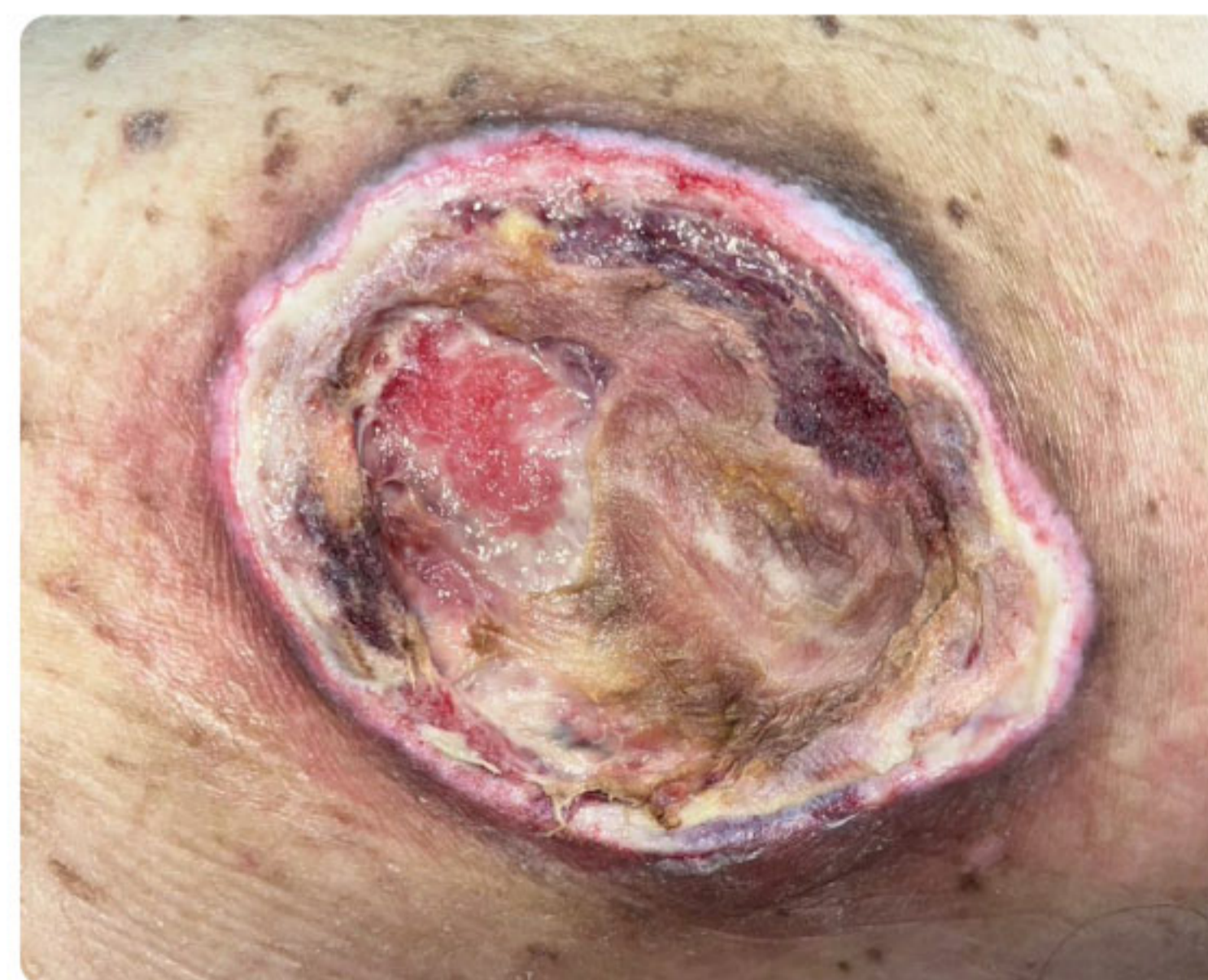PROGRESS



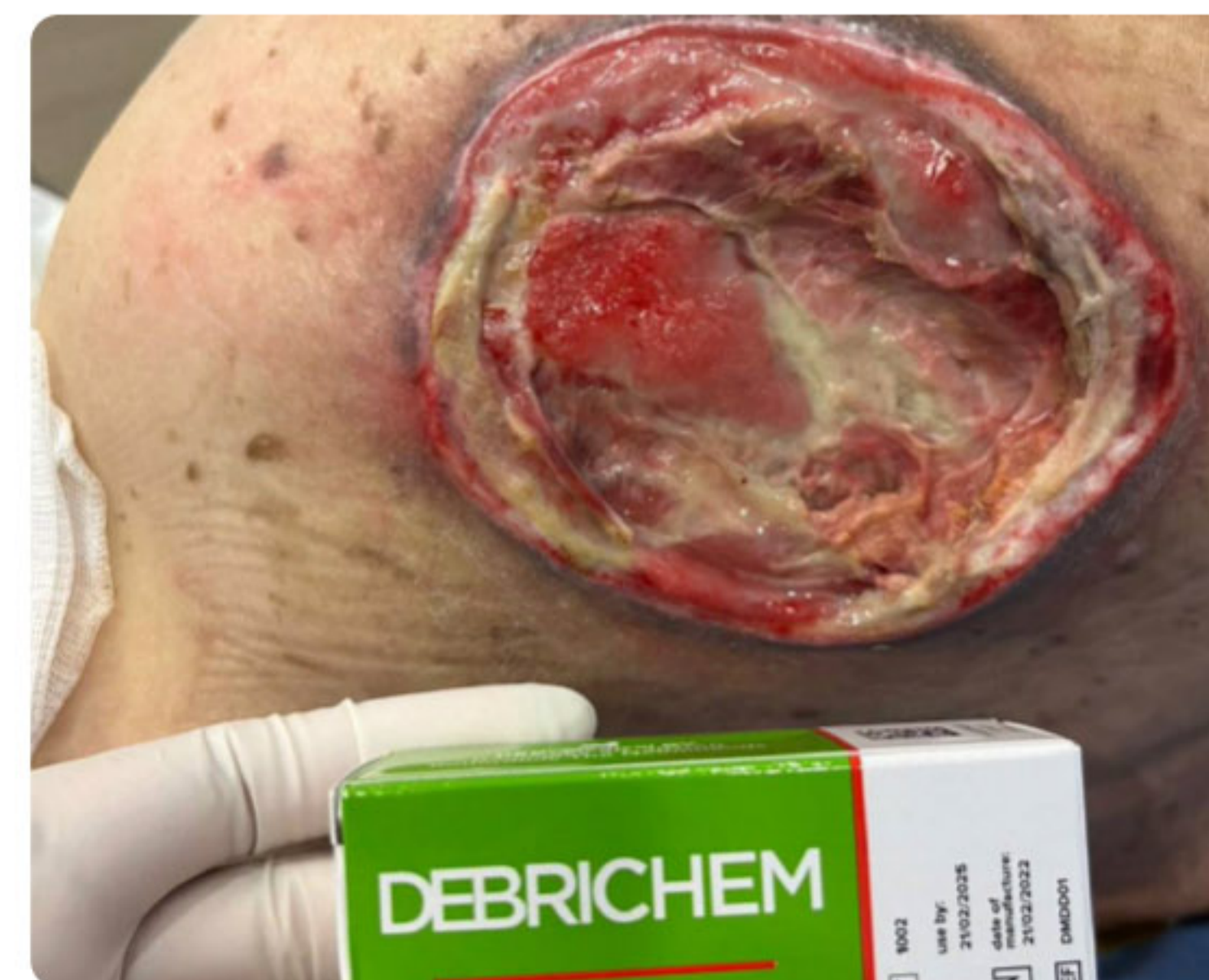A Figure A: During applicaiton



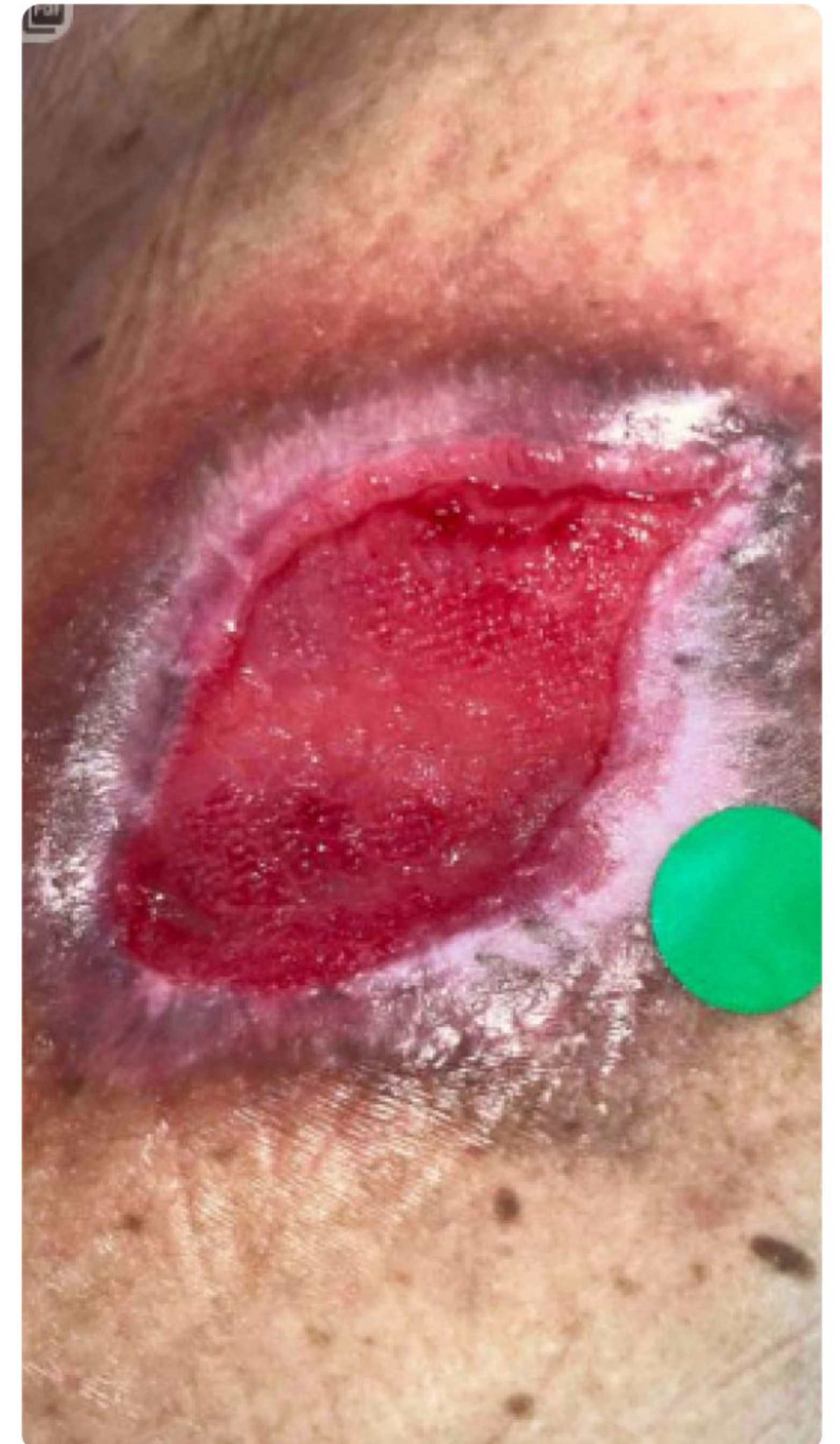B Figure B: 1 week post DEBRICHEM



C Figure C: 3 weeks post DEBRICHEM



D Figure D: 5 weeks post DEBRICHEM - a new application



E Figure E: 3 months post second application



CASE 43

101- YEAR-OLD MALE WITH
A PRESSURE ULCER ON THE LEFT HEEL

AUTHOR

PHRAMONGKUTKLAO HOSPITAL, THAILAND

ETIOLOGY

PRESSURE ULCER



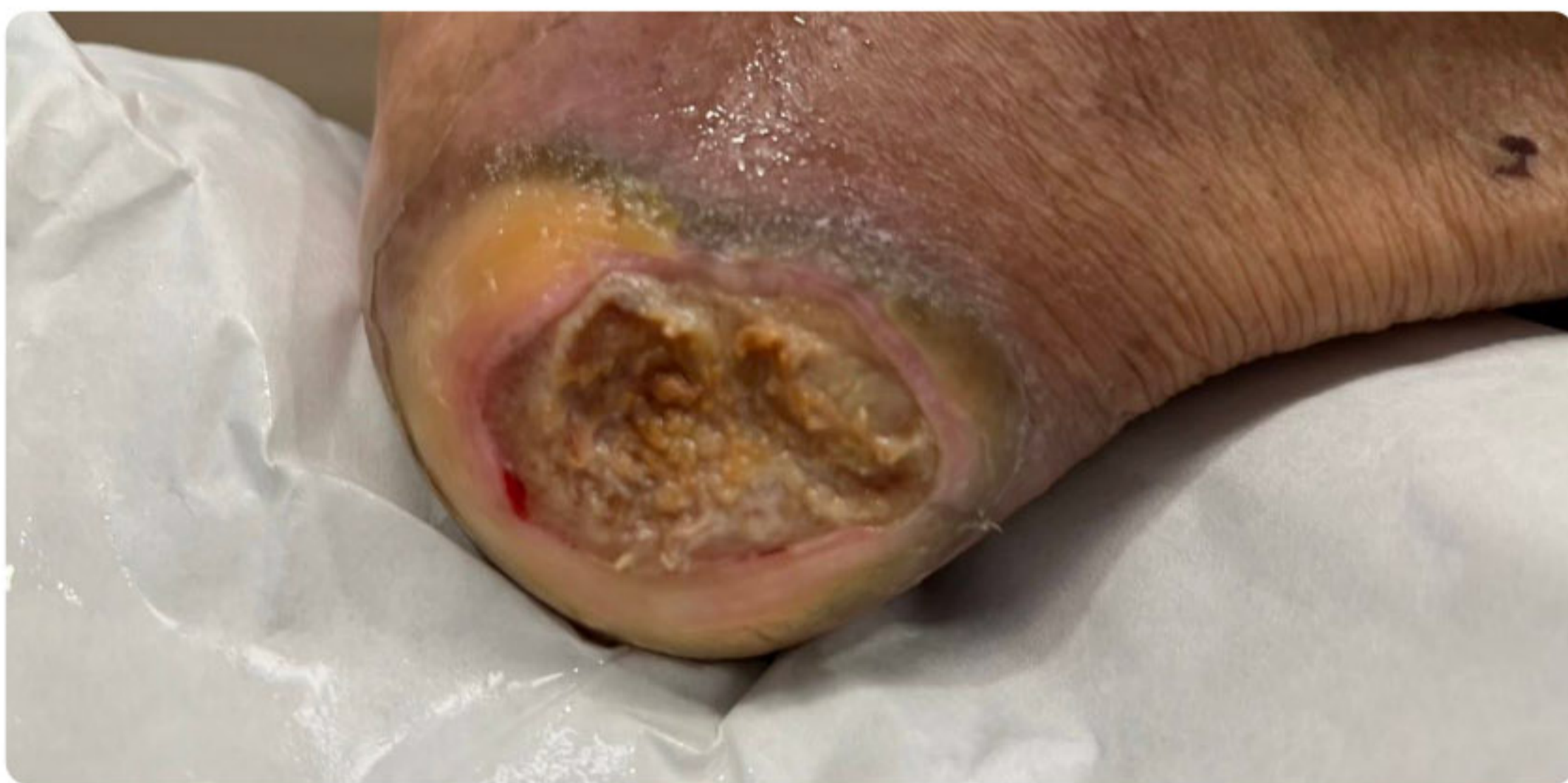GENERAL MEDICAL HISTORY

- ✓ Diabetes mellites
- ✓ Dyslipidaemia
- ✓ Hypertension
- ✓ Dementia
- ✓ Alzheimer's
- ✓ Benign prostate hyperplasia
- ✓ Chronic kidney disease

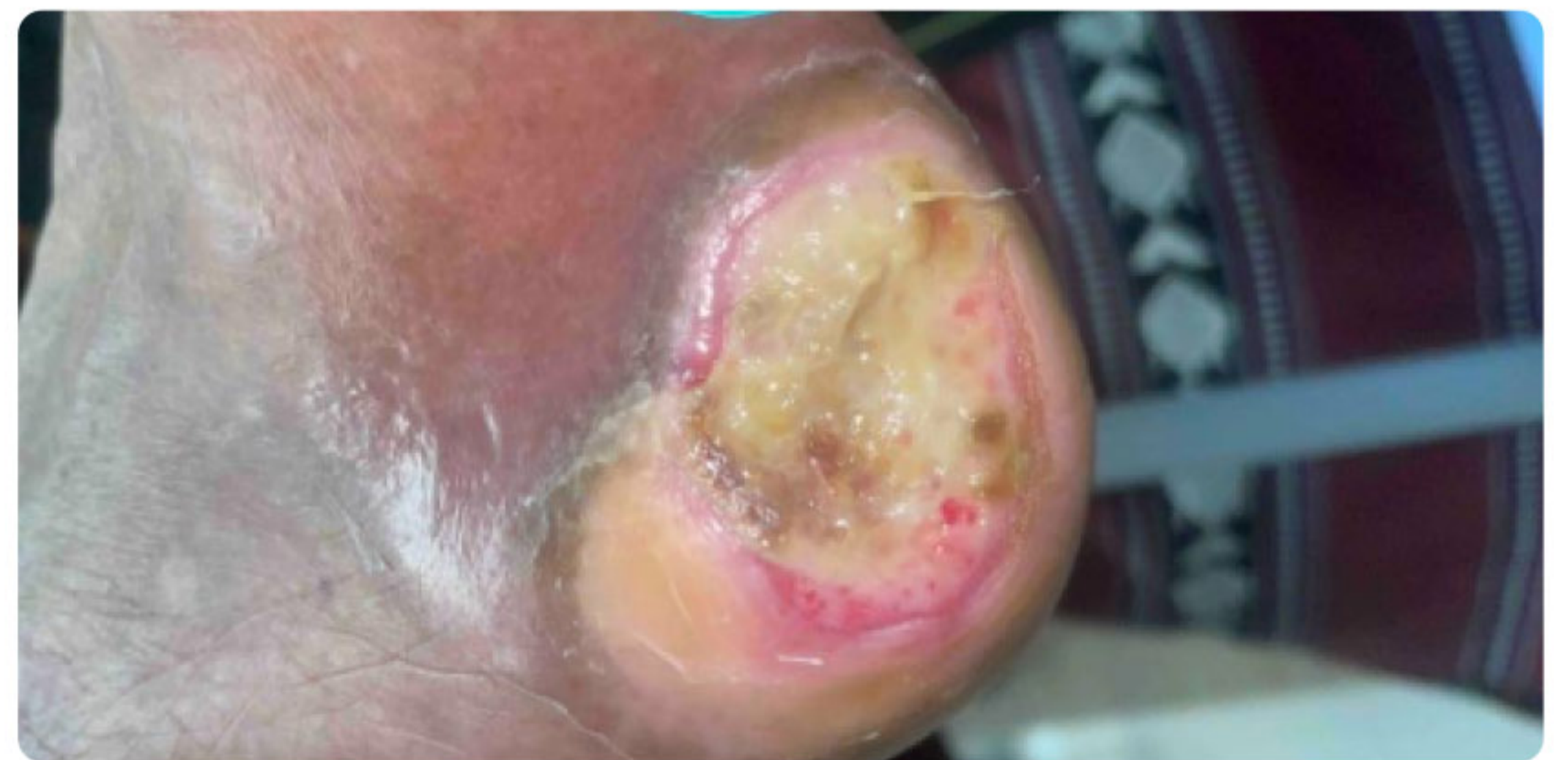DESCRIPTION

A 101-year-old male presented in clinic with a pressure ulcer on the left heel. The patient has a wide range of comorbidities among which Diabetes mellites, Dyslipidaemia, Hypertension, Dementia, Alzheimer's, Benign prostate hyperplasia and Chronic kidney disease. The wound presented with a sloughy eschar scab on the heel (Figure A). The pressure ulcer was treated with DEBRICHEM showing a dried out area with sharp edges of the wound bed (Figure B). The removal of the infection by the chemical debridement initiated a good progression in wound healing having a fully granulated wound bed in 1,5 months (Figure C). After 3,5 months the ulcer showed almost complete closure. It has been treated with standard of care dressing to control the right moisture balance to maintain optimal wound environment and facilitate healing, in addition offloading was done to have good perfusion to the wound bed.

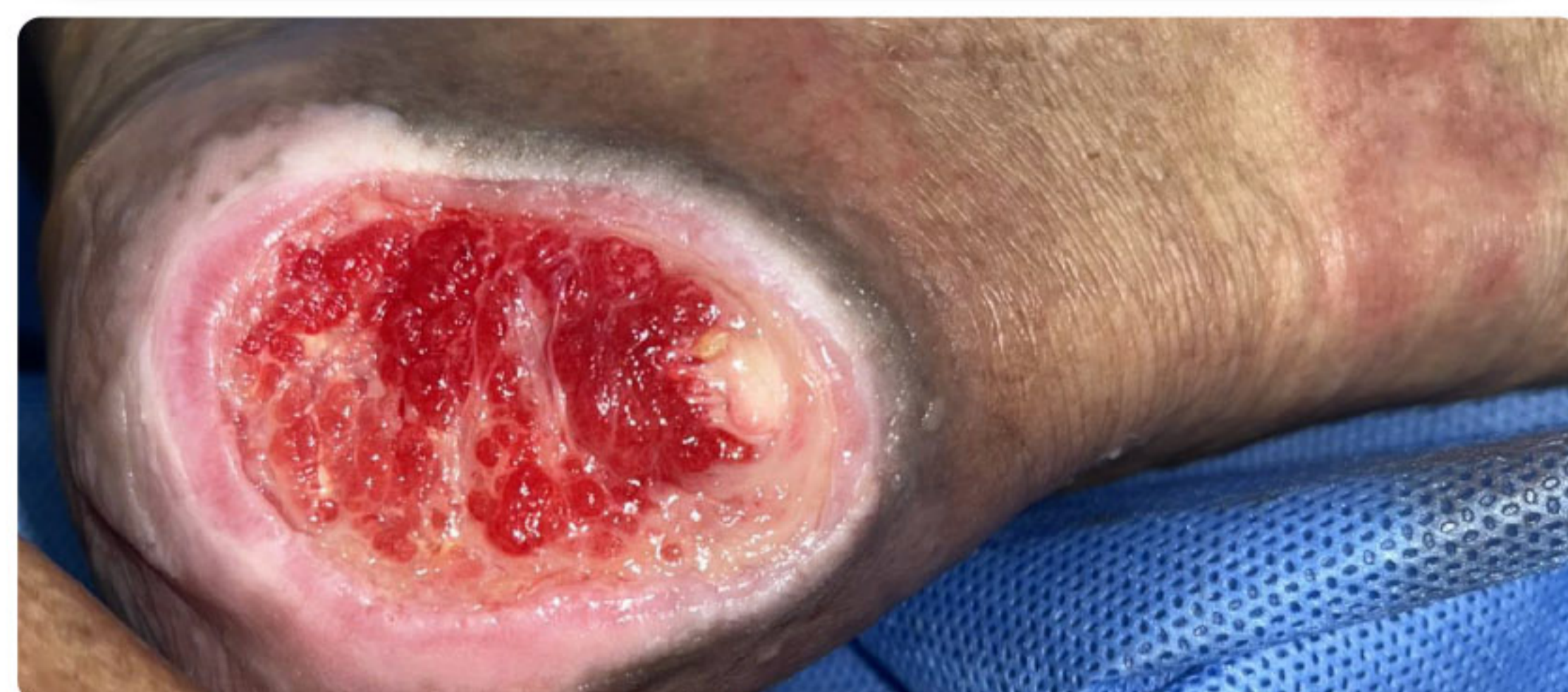PROGRESS



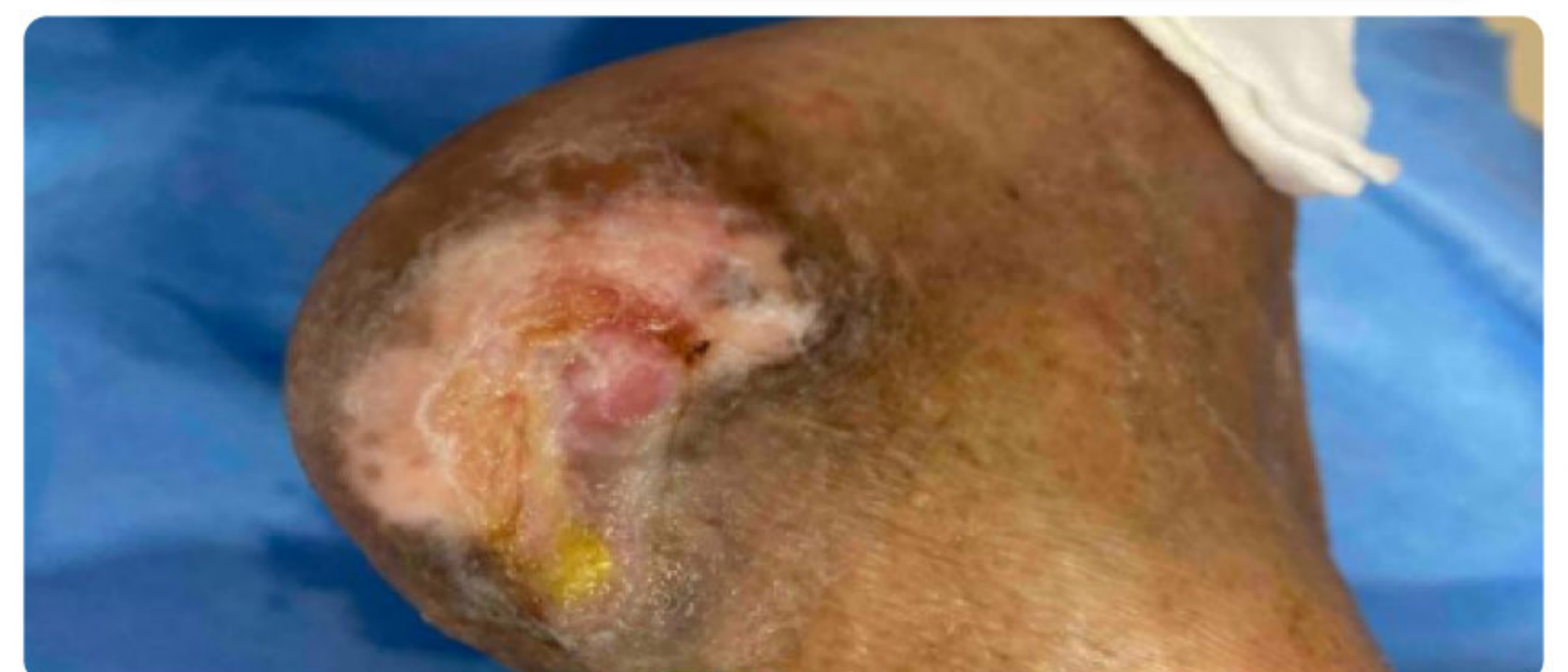A Figure A: At presentation



B Figure B: 1 day post DEBRICHEM



C Figure C: 1,5 months post DEBRICHEM



D Figure D: 3,5 months post second application



CASE 50

65- YEAR-OLD MALE WITH SACRAL
PRESSURE ULCER

AUTHOR

S. AMESZ, DEVENTER ZIEKENHUIS,
NETHERLANDS

ETIOLOGY

PRESSURE ULCER



GENERAL MEDICAL HISTORY

- ✓ Diabetes Mellites resolved by lifestyle change
- ✓ Psoriasis
- ✓ Spinal cord injury (Th 10)
- ✓ Hypercholesterolemia
- ✓ Hypertension

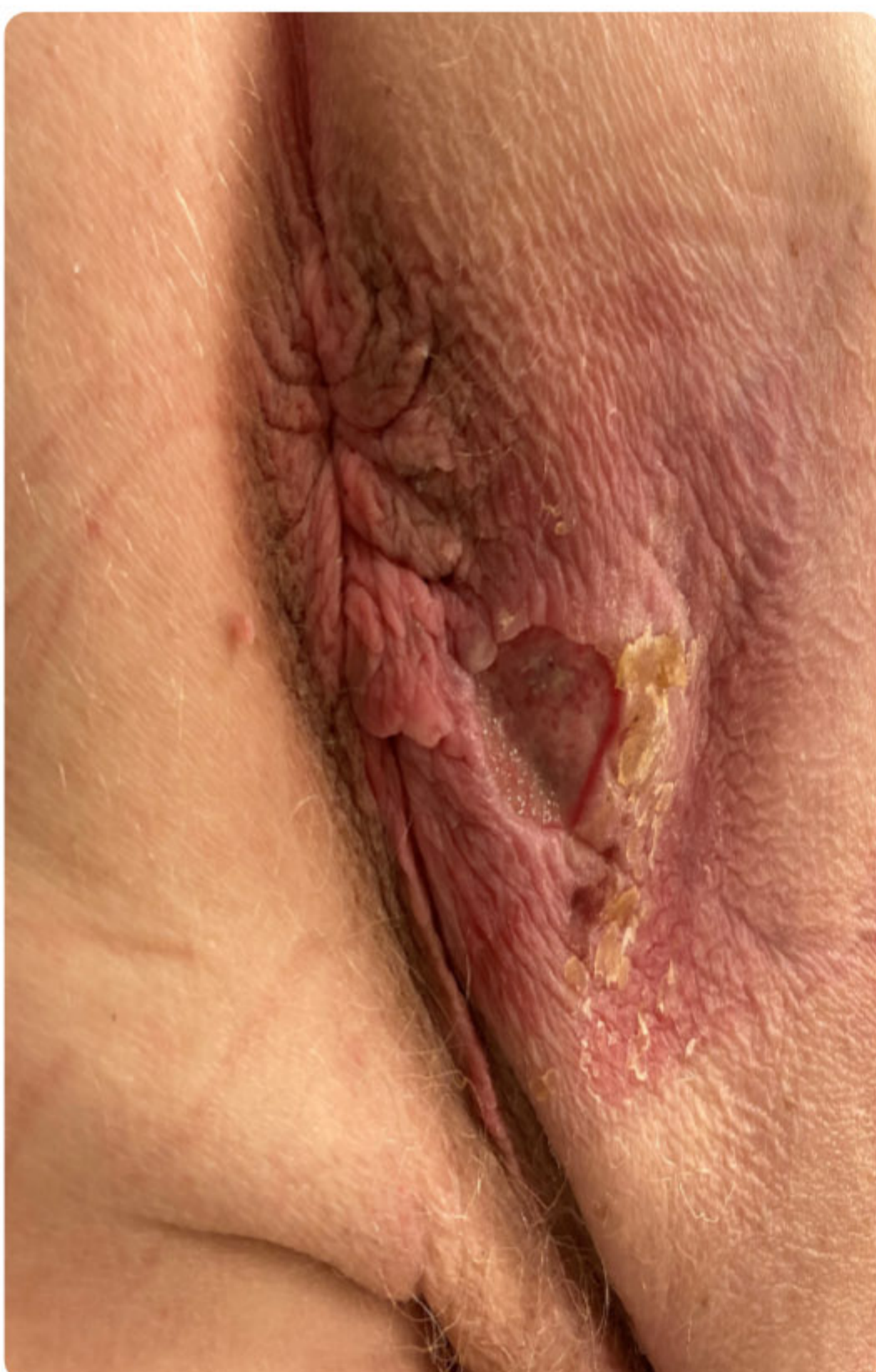DESCRIPTION

A 65-year-old male patient presented with a pressure ulcer located on the sacrum, which had been persistent for 28 weeks (Figure A). The occurrence of the lesion was attributed to a spinal cord injury at the level of vertebrae Th10. Preceding the DEBRICHEM treatment, offloading measures were implemented to alleviate pressure on the affected area.

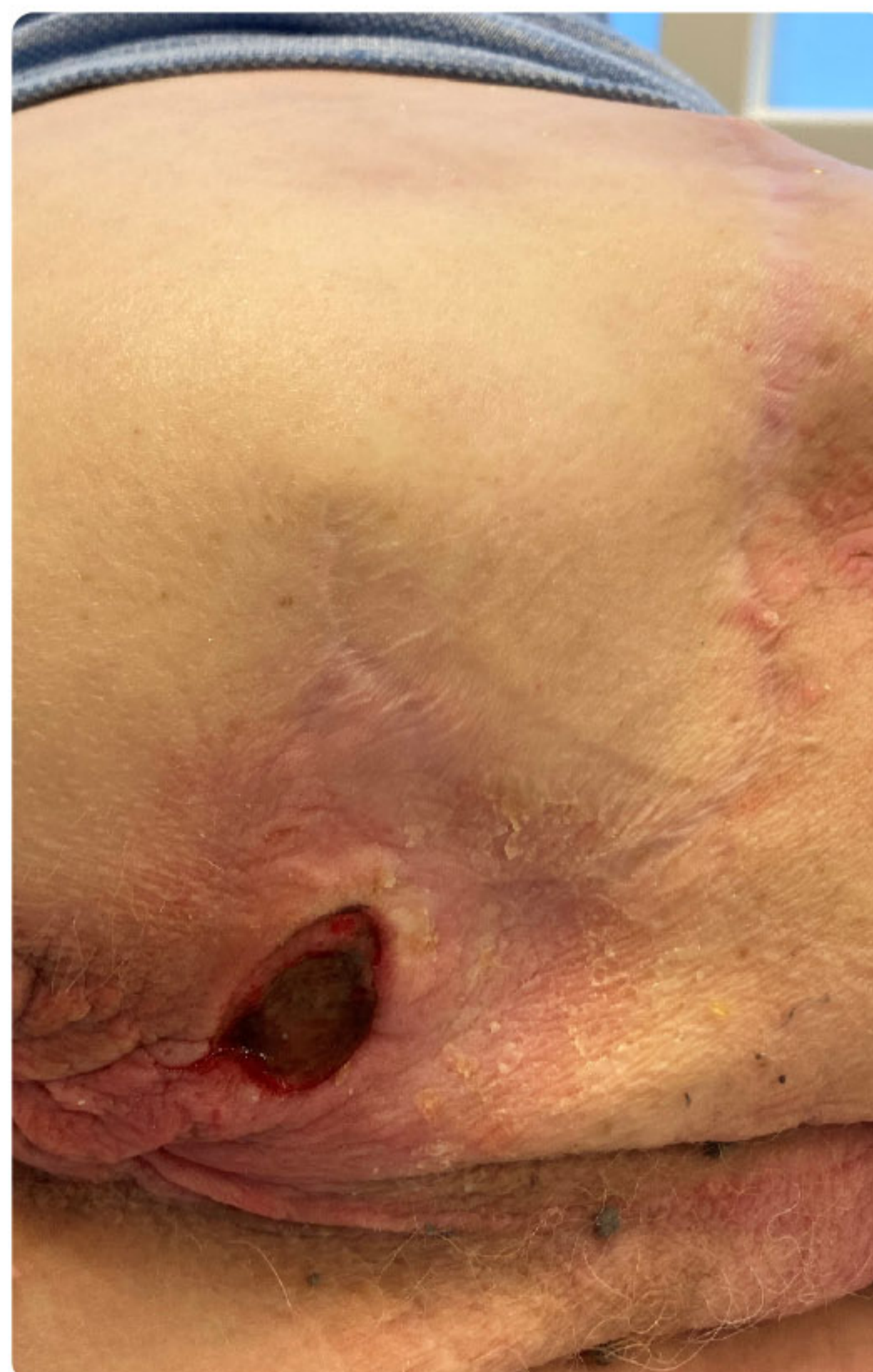Over the initial eight-week period, wound development was notably slow, primarily attributed to suboptimal compliance on the part of the patient. Despite efforts to optimize wound management, progress was hindered by challenges in patient adherence to prescribed treatment protocols. Subsequently, a new DEBRICHEM treatment was administered after 8 weeks (Figure B).

This was followed by flap reconstruction to facilitate complete closure of the wound 2 weeks later (Figure C). Throughout the treatment course, the patient did not report any associated pain up to lesion closure.

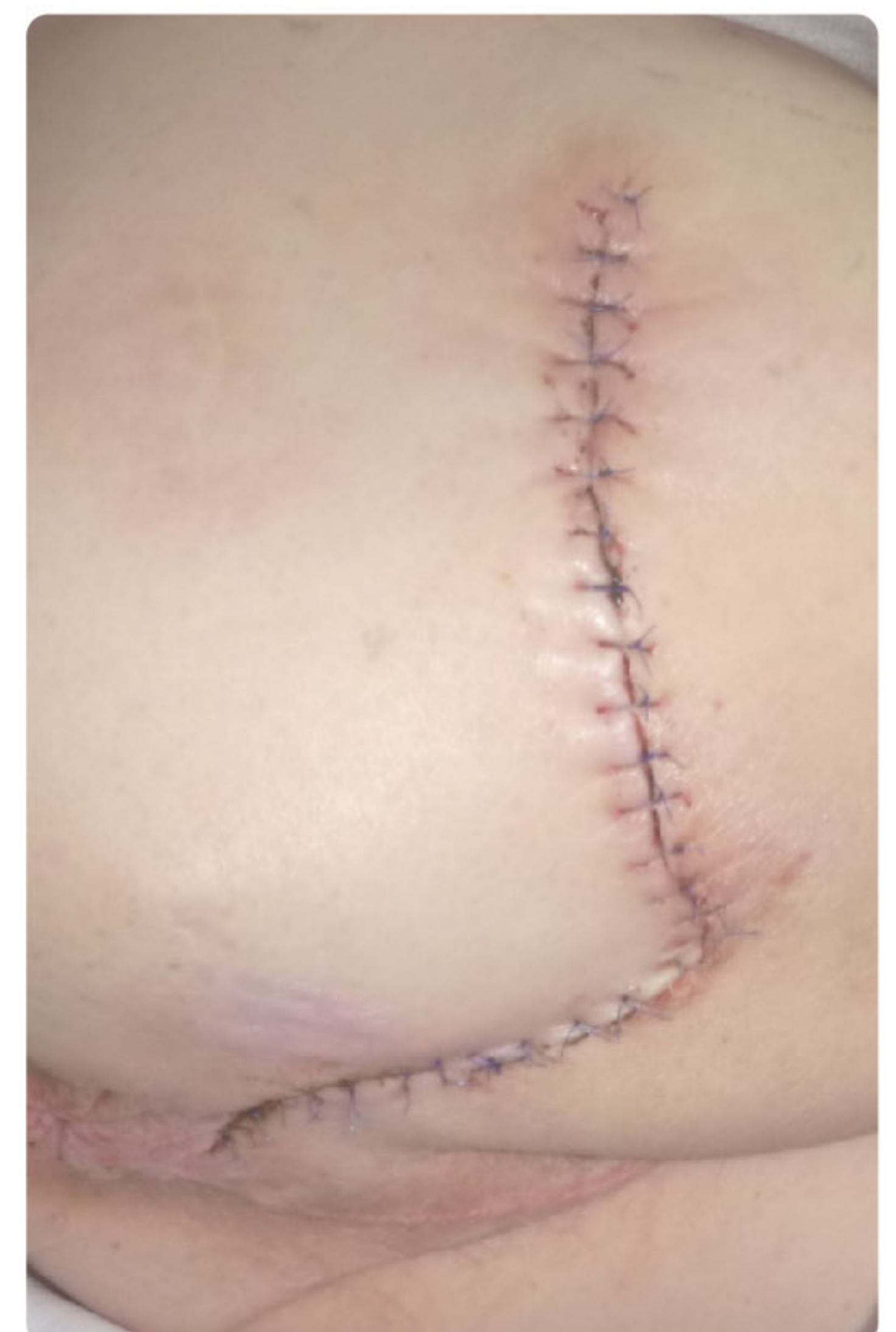PROGRESS



1. Figure A: After Application



2. Figure B: After 8 weeks new DEBRICHEM application



3. Figure C: 10 weeks post 1st DEBRICHEM



CASE 5

79- YEAR-OLD FEMALE WITH
A VASCULITIC ULCER ON THE RIGHT FOOT

AUTHOR

DR. A.COGO, VILLA BERICA, ITALY

ETIOLOGY

VASCULITIC ULCER



GENERAL MEDICAL HISTORY

- ✓ Severe right foot infection
- ✓ Acute lymphatic leukaemia
- ✓ Hypertension
- ✓ Aplastic anaemia

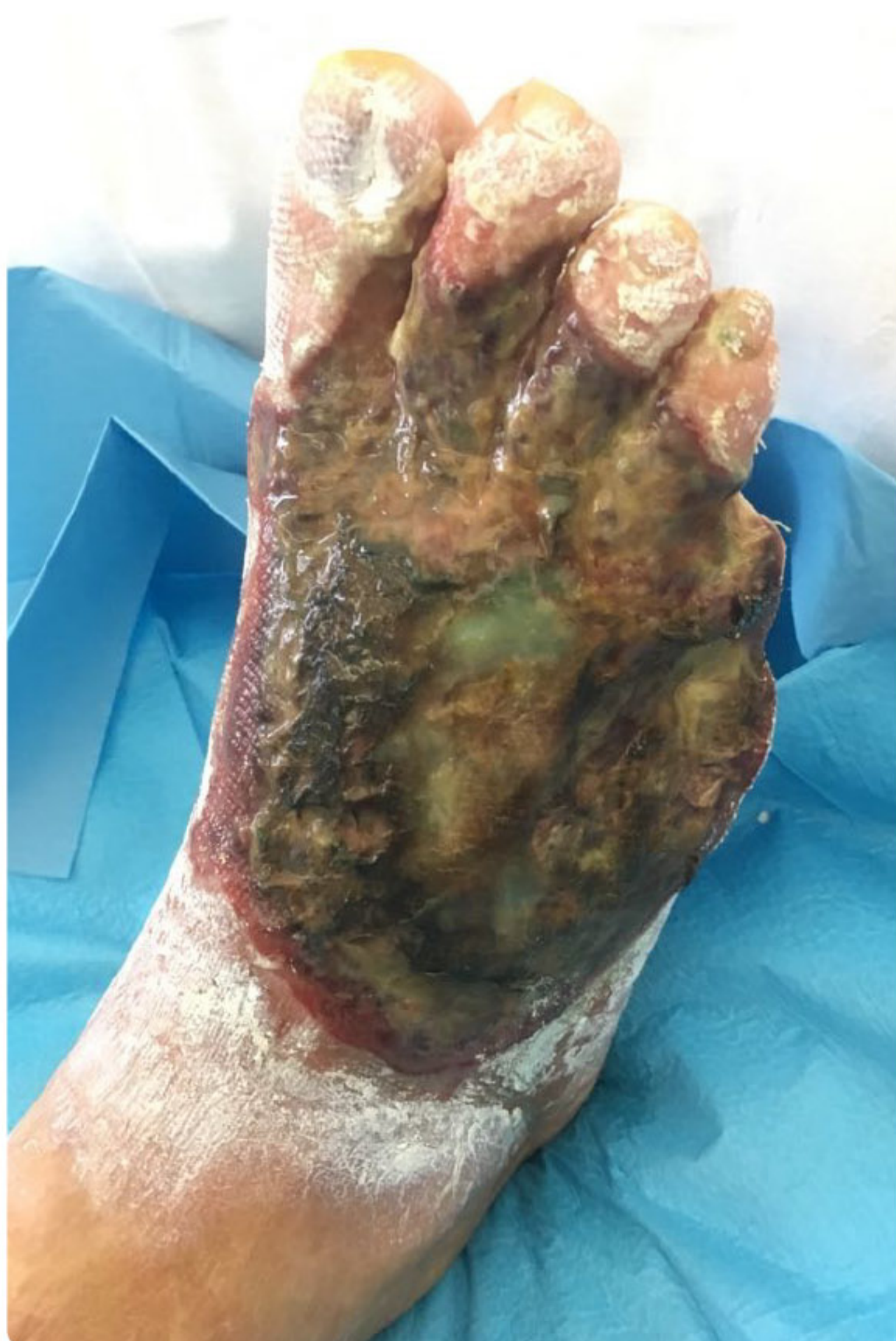DESCRIPTION

The vasculitic ulcer was located on the right fore foot and had been present for 6 weeks when the patient visited the clinic for DEBRICHEM treatment. The lesion was severely infected. The ulcer has only been treated on a conservative approach prior to DEBRICHEM application. The infection was visible due to a green expression of the wound bed (figure A).

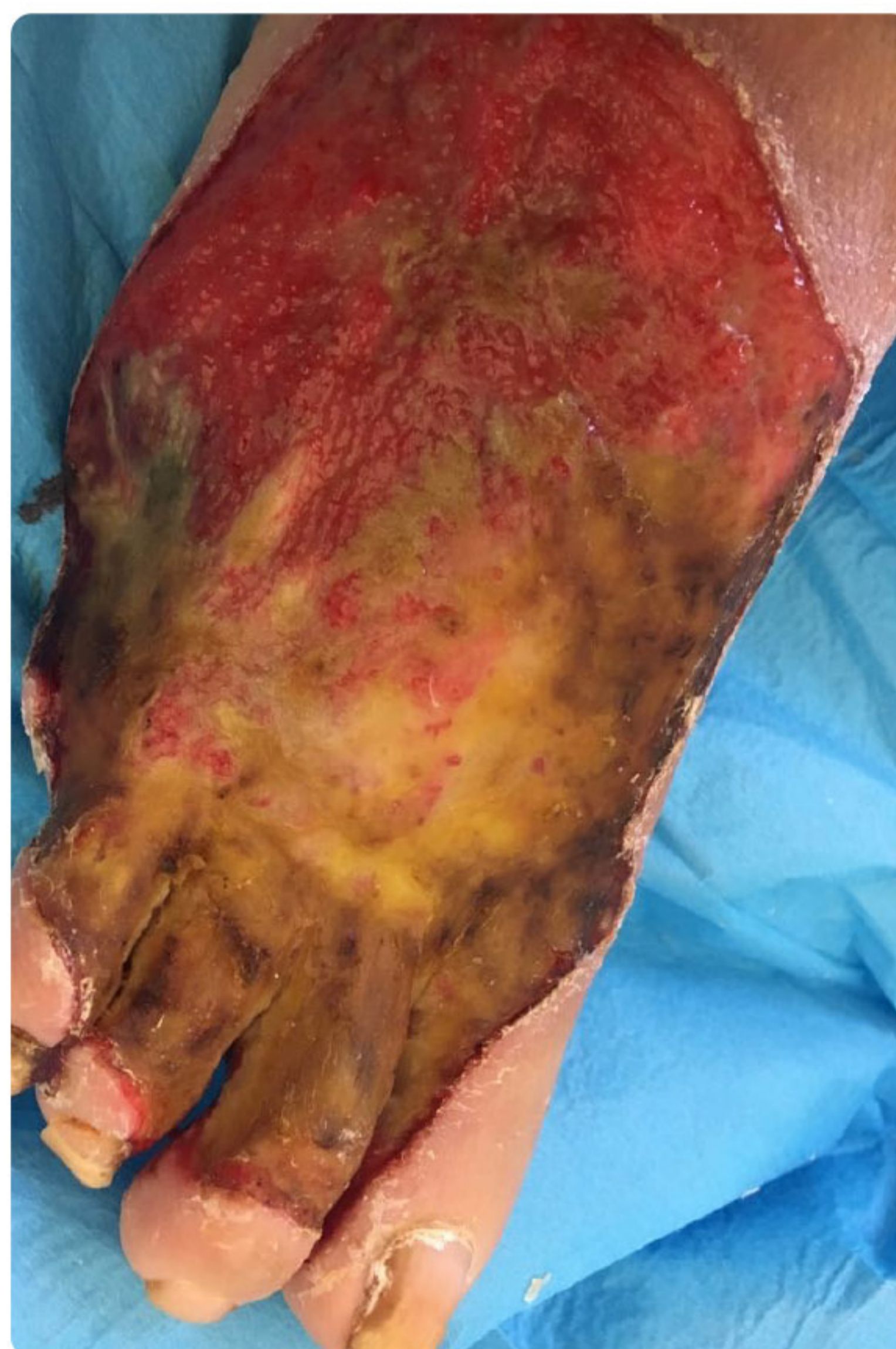
The lesion has been treated with DEBRICHEM and bandaged. After 21 days granulation was visible in the wound bed (figure B) In these 21 days the bandages have been changed frequently according standard of care. Seven days later, at day 28, good granulation was persistent and no signs of reinfection (Figure C).

The patient has been lost for follow up after day 28, because she was transferred to another hospital.

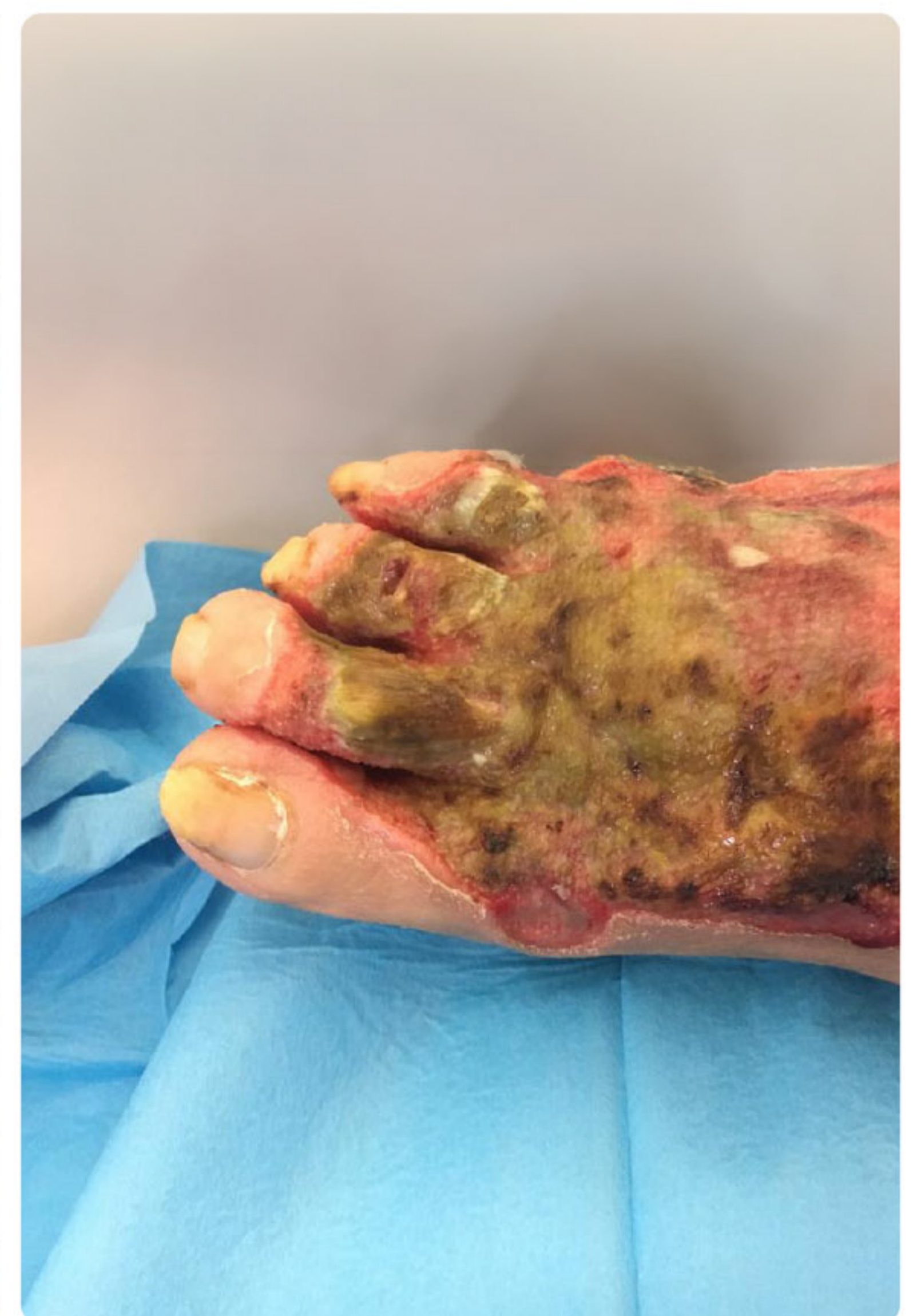PROGRESS



1. Figure A: At presentation



2. Figure B: 3 weeks post DEBRICHEM



3. Figure C: 28 days post application



CASE 18

72- YEAR-OLD FEMALE WITH A LEFT ANKLE
POST TRAUMATIC ULCER

AUTHOR

DR. A.COGO, VILLA BERICA, ITALY

ETIOLOGY

POST TRAUMATIC ULCER



GENERAL MEDICAL HISTORY

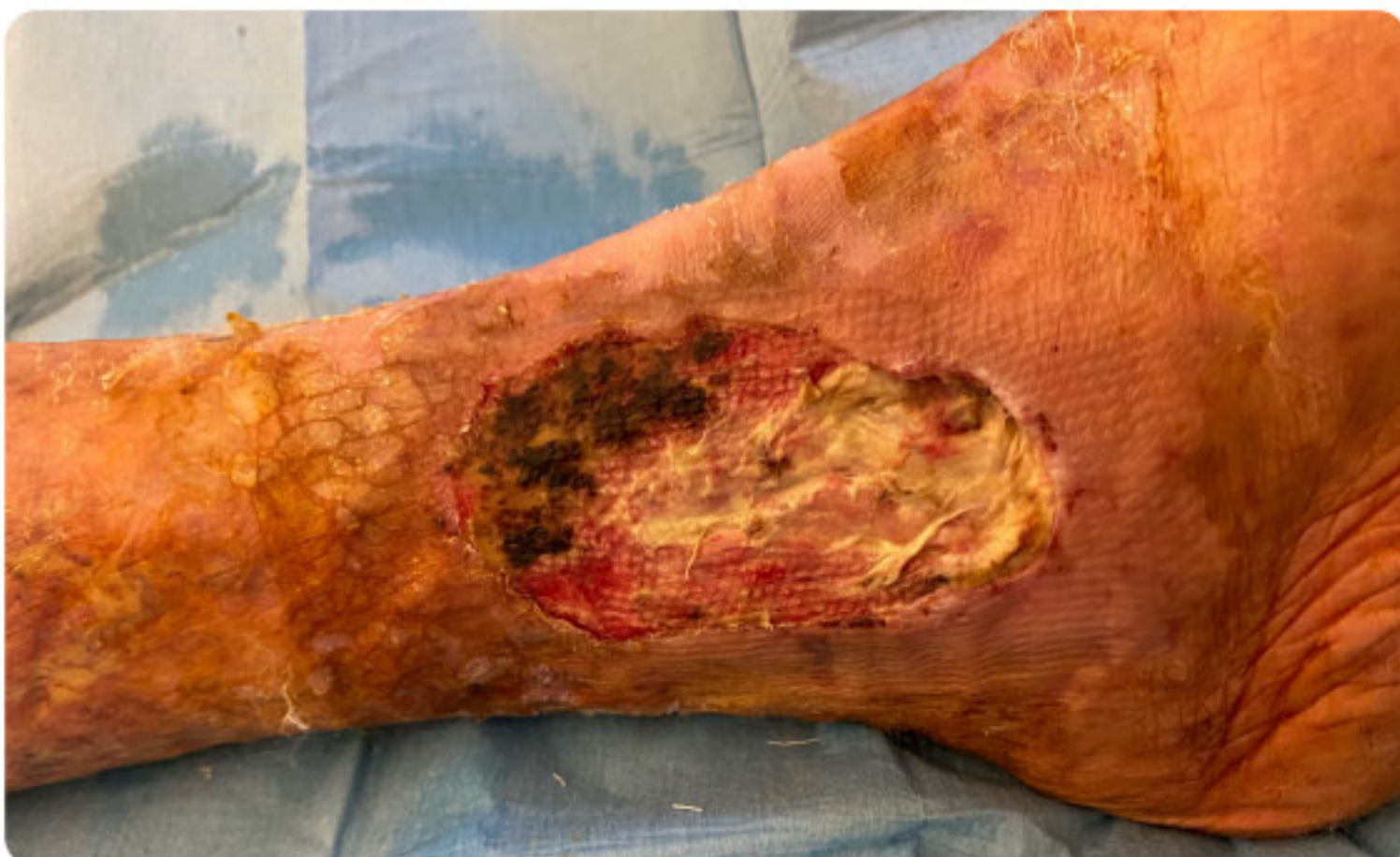- ✓ Arteriopathy
- ✓ Venous insufficiency
- ✓ Hypertension
- ✓ Diabetes Mellitus
- ✓ Anaemia

DESCRIPTION

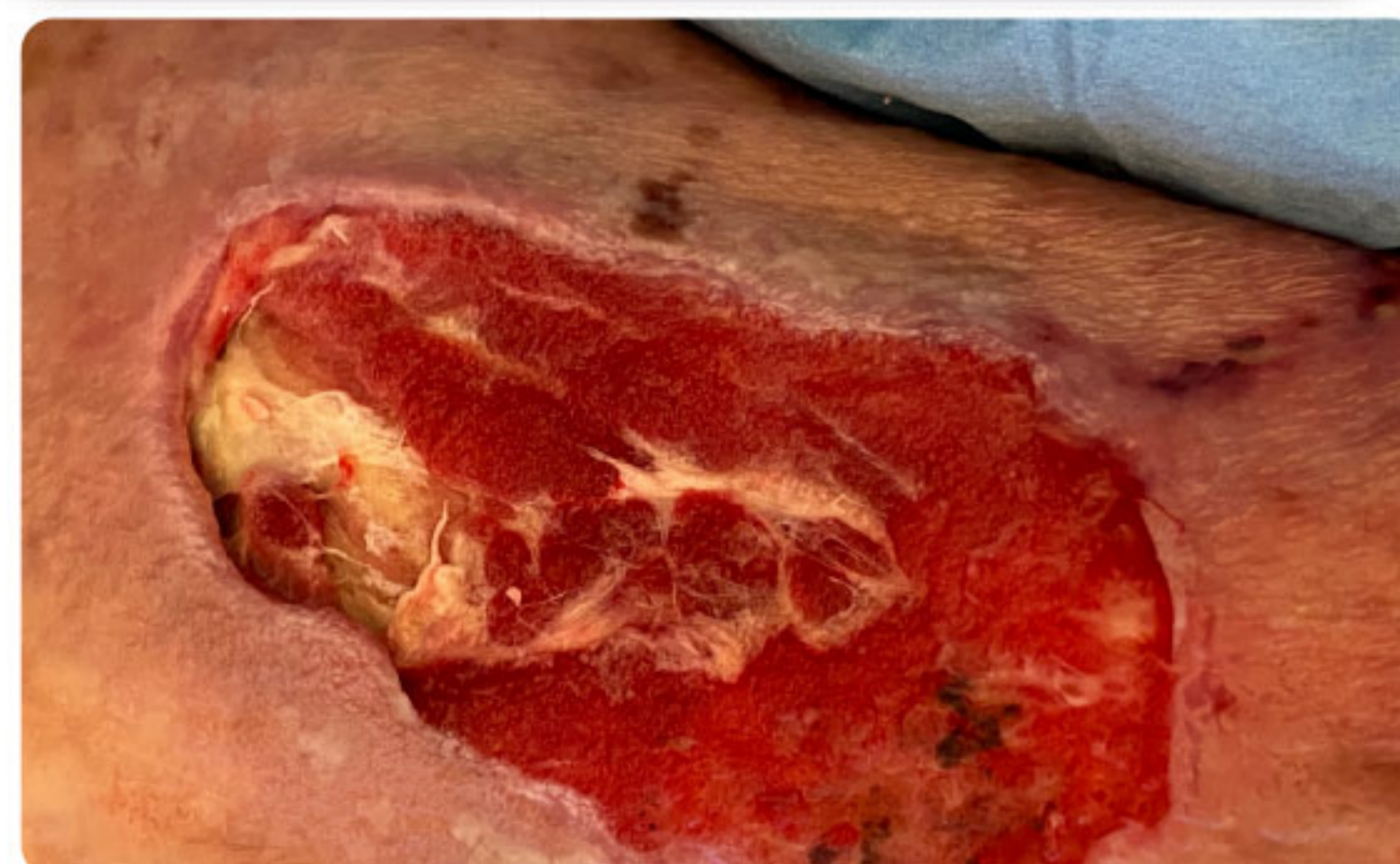The patient entered the clinic with a lesion on left ankle. The wound started as a traumatic lesion. The patient is known with arterial and venous insufficiency. The wound evolved into an ulcer and rapidly became infected with among others entobacter cloacae. The wound has bone exposure in the lower part of the wound. The dressings used prior to debridement and antibiotic therapy did not have any effect and the wound was even progressively deteriorating. An endovascular revascularisation was performed and followed with a debridement with DEBRICHEM. The bone exposure become more prominent.

Immediately after debridement VAC therapy was started. After 3 days the dressing change of the VAC therapy was performed (Figure A). 7 days after DEBRICHEM application the VAC therapy was terminated and the wound bed showed full granulation (Figure B). Treatment after the VAC therapy was set at a weekly change of Vaseline gauze dressings. Two month post DEBRICHEM treatment the wound bed showed growing granulation and decrease of the wound size (Figure C). After 3 months the wound bed showed complete healing (Figure D). During the entire treatment after debridement with DEBRICHEM no antibiotic treatment has been used.

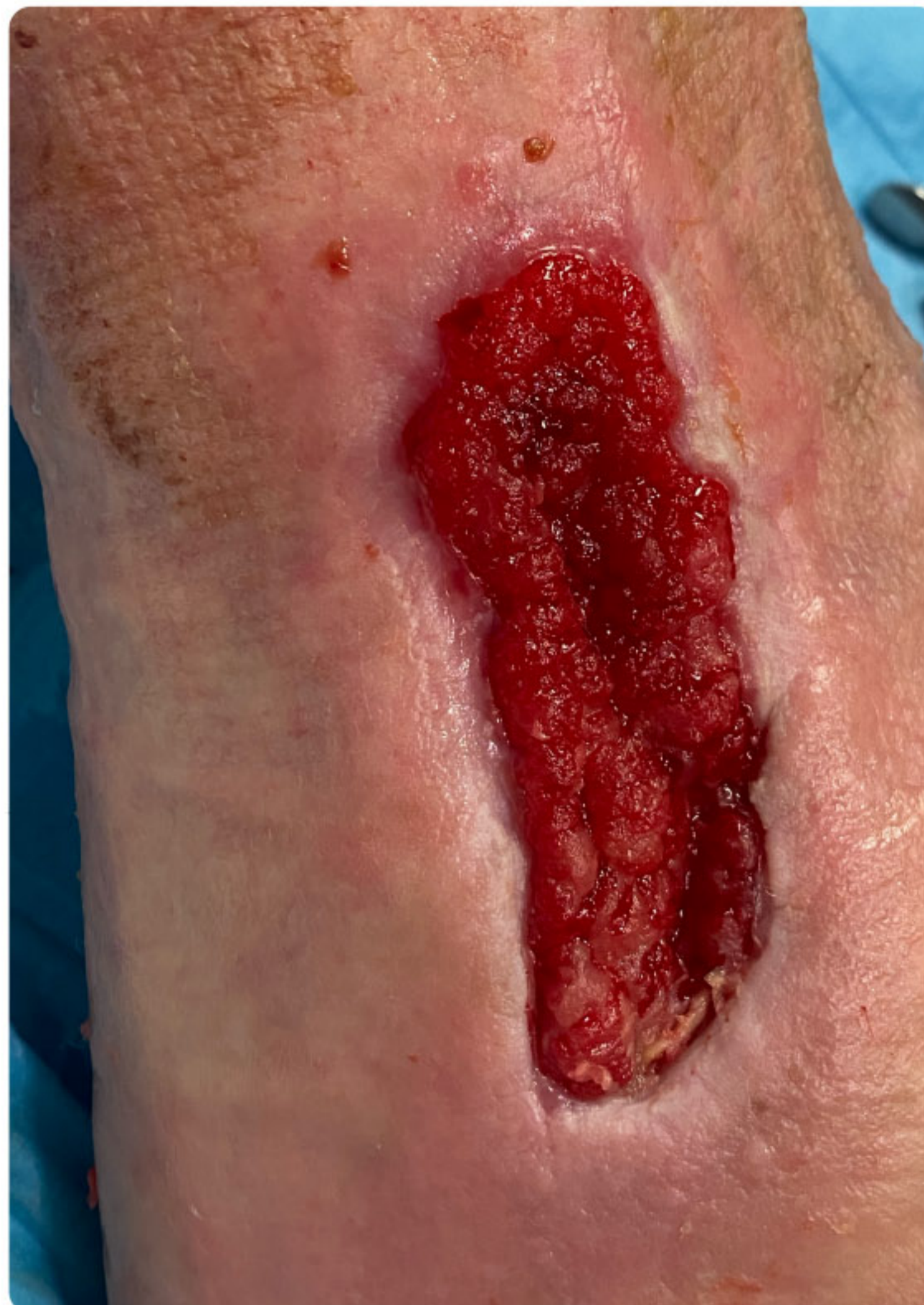PROGRESS



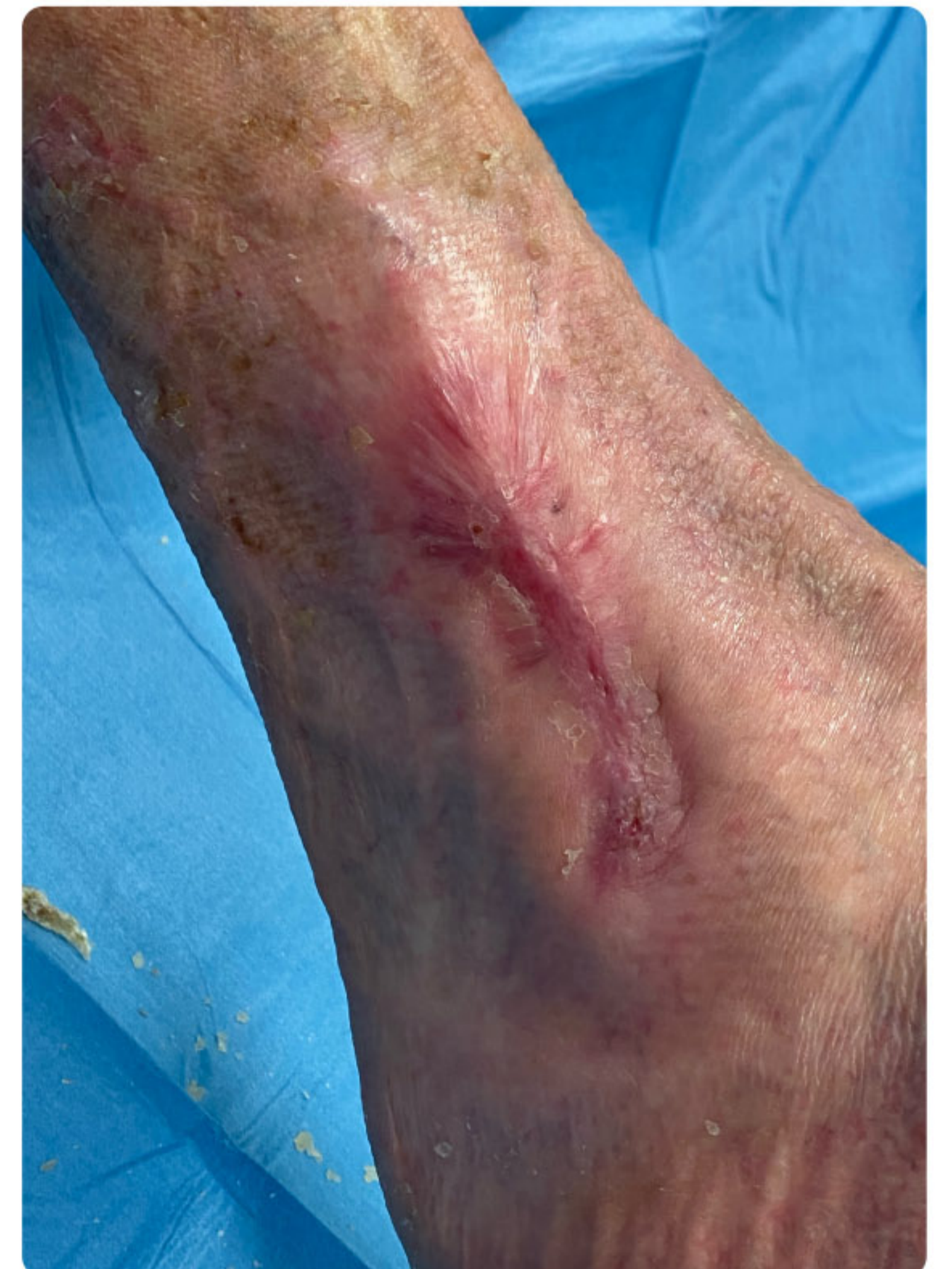1. Figure A: 3 days Post DEBRICHEM



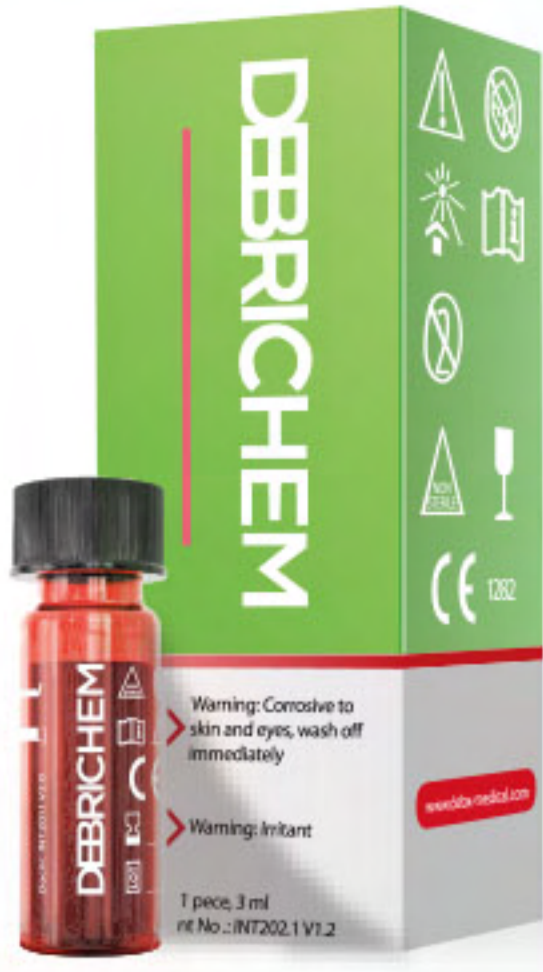2. Figure B: 7 days Post DEBRICHEM



3. Figure C: 2 months Post DEBRICHEM



4. Figure D: 3 months Post DEBRICHEM



CASE 28

72- YEAR-OLD FEMALE. SURGICAL WOUND DEHISCENSE INFECTED ON LEFT LOWER LEG

AUTHOR

PROF. H. NAIR,
HOSPITAL KUALA LUMPUR, MALAYSIA

ETIOLOGY

POST TRAUMATIC ULCER



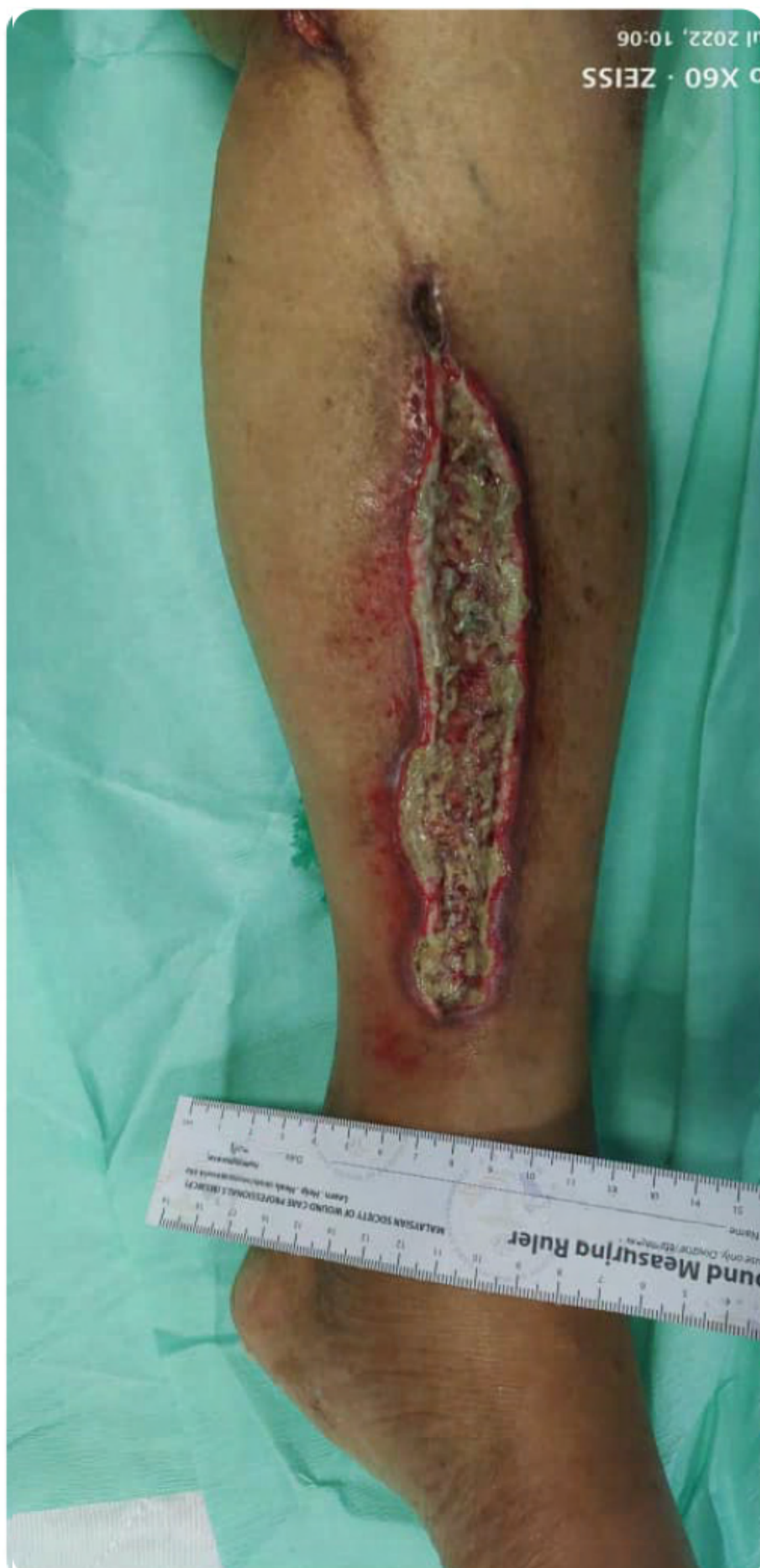GENERAL MEDICAL HISTORY

- ✓ Diabetes mellitus
- ✓ Coronary artery bypass graft surgery

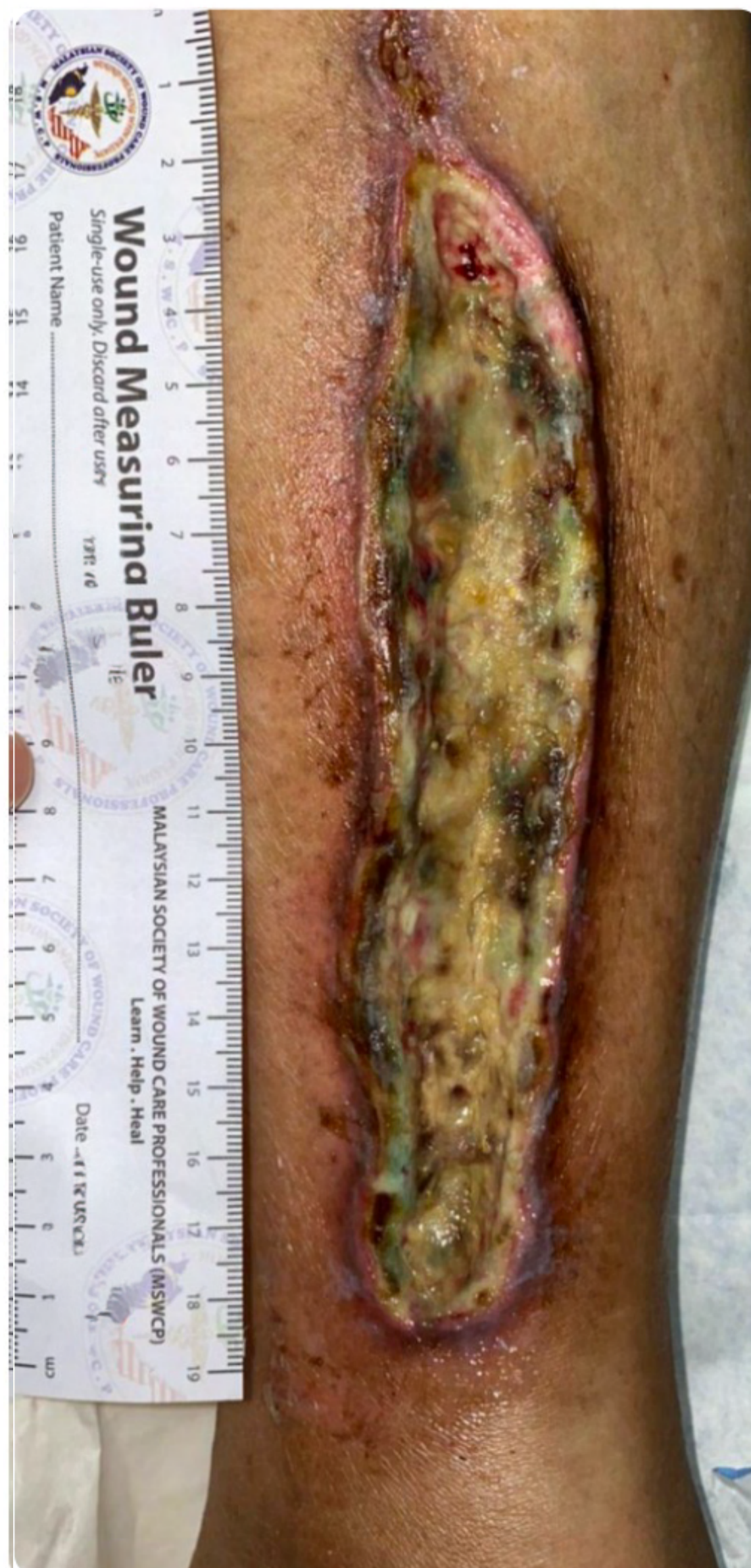DESCRIPTION

Patient, with a history of diabetes mellitus for over 10 years presented with wound dehiscence post coronary artery bypass graft surgery. The wound had been present for 11 weeks and had been previously treated with Manuka honey dressing and silver alginate hydrogel, with limited success. The wound measured 16.5 x 2.5cm at the time of presentation (Figure A). Treatment was initiated with DEBRICHEM and the wound bed showed significant improvement 5 days after application (Figure B). The pain measured via Visual Analogue scale (0-10) was a 2 before, 5 during, and 0 after treatment, Topical Lidocaine crème was used for anaesthesia. Follow-up treatment consisted of changing Vaseline gauze at least twice a week . In 5 weeks, full granulation of the wound bed was observed (Figure C). The wound remained granulated and showed good indications of healing at the one-week follow-up visits. 9 weeks post-DEBRICHEM, the wound had reepithelialised far enough to discharge the patient (Figure D). DEBRICHEM was found to be effective in the treatment of this chronic wound, which had previously shown limited response to other treatments.

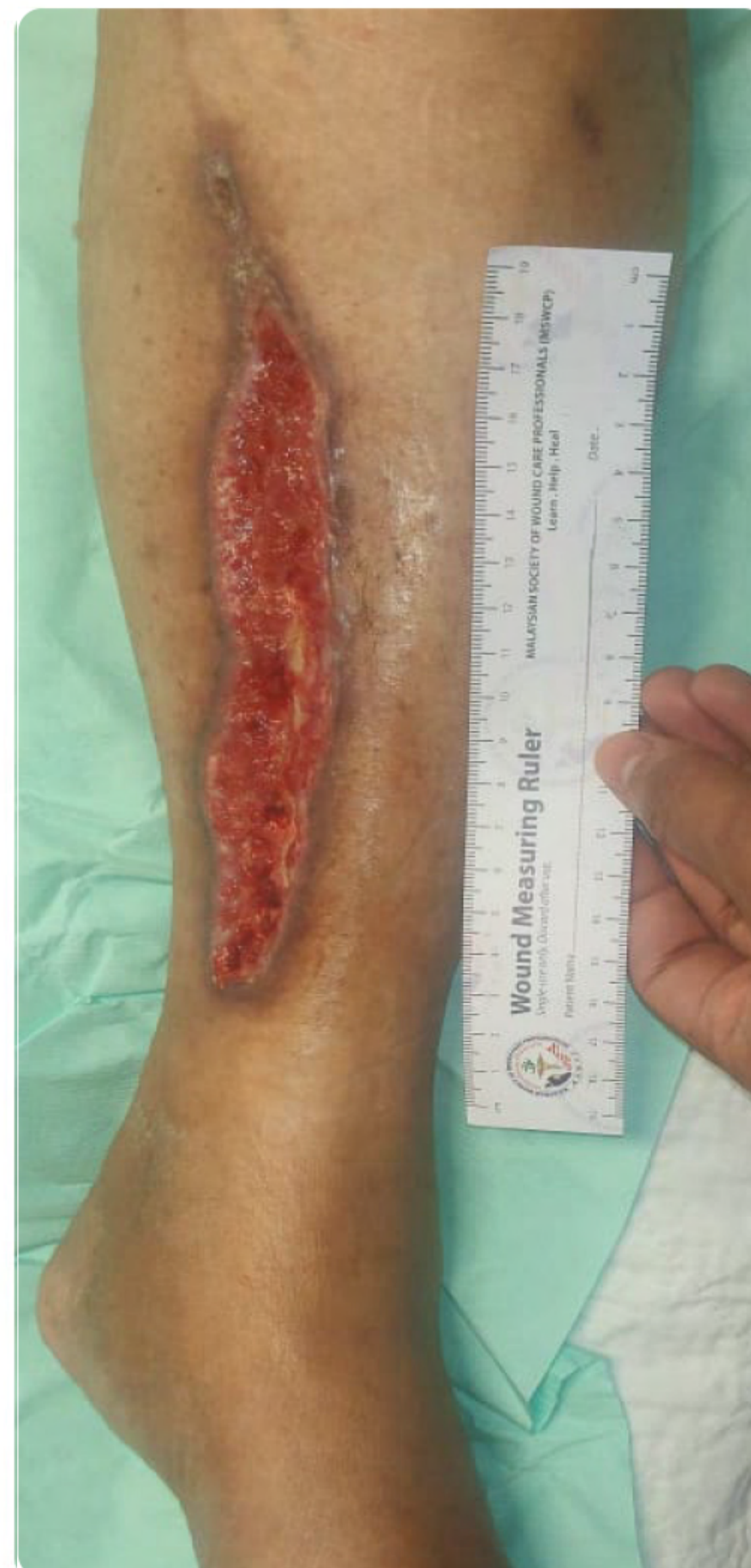PROGRESS



1. Figure A: Wound presented prior to DEBRICHEM application



2. Figure B: post-DEBRICHEM application



3. Figure C: Wound 5 weeks post-DEBRICHEM application



4. Figure D: Wound 9 weeks post-DEBRICHEM application



CASE 45

45- YEAR-OLD MALE WITH LEFT HEEL
POST TRAUMATIC ULCER

AUTHOR

DR. NUTTAWUT SERMSATHANASAWADI,
MAHIDOL HOSPITAL, THAILAND

ETIOLOGY

POST TRAUMATIC ULCER



GENERAL MEDICAL HISTORY

- ✓ Diabetes Mellites
- ✓ Hypertension

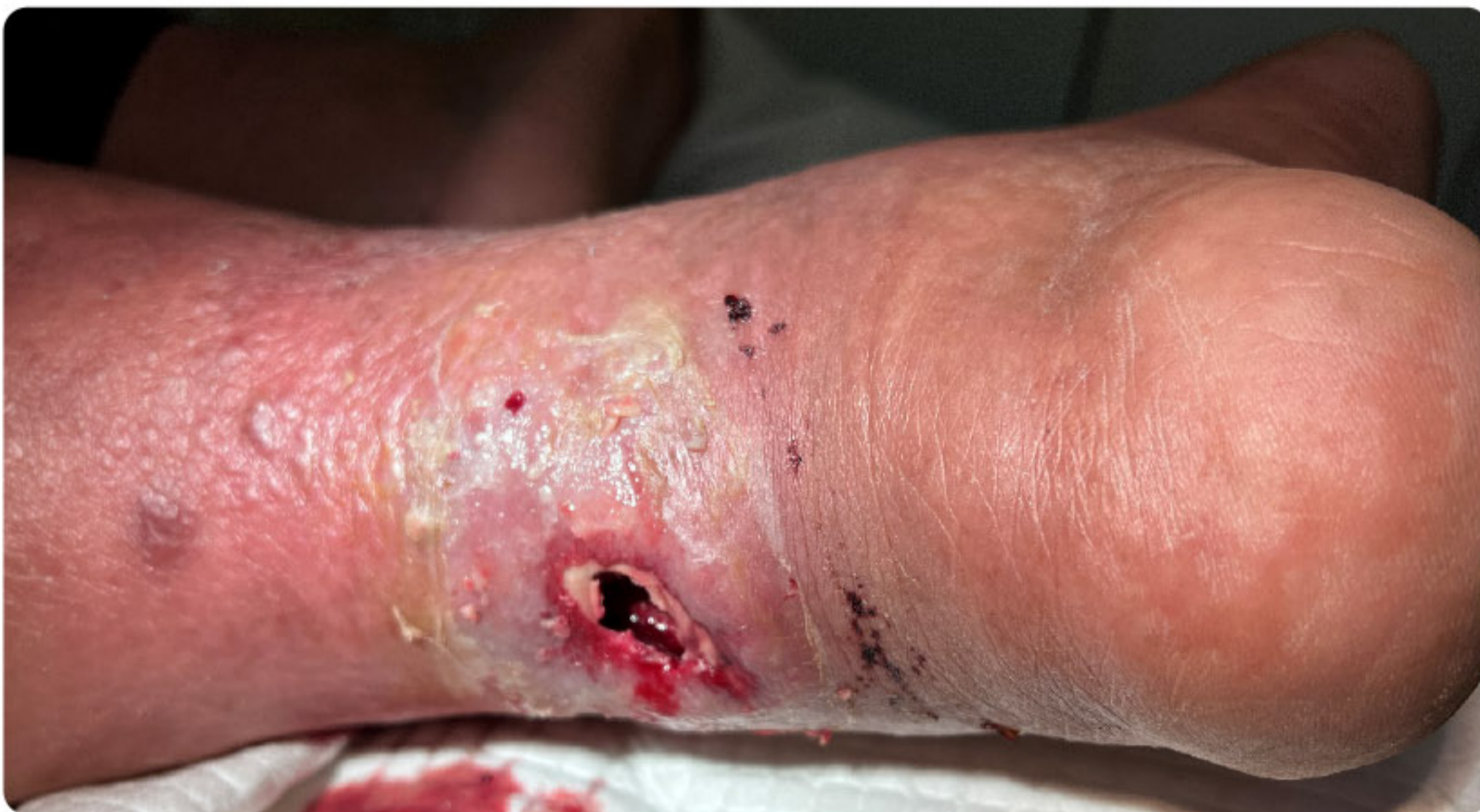DESCRIPTION

A 45-year-old male with a history of Diabetes mellites and hypertension presented with an abscess of 3 cm on the left heel (Figure A). The abscess was incised and drained with 15 cc of material. After 2 weeks it developed into an ulcer during the visit the ulcer was assessed (Figure B) and treated with DEBRICHEM. The Ankle Brachial index was 0.8. the wound dressing used up to was silver alginate.

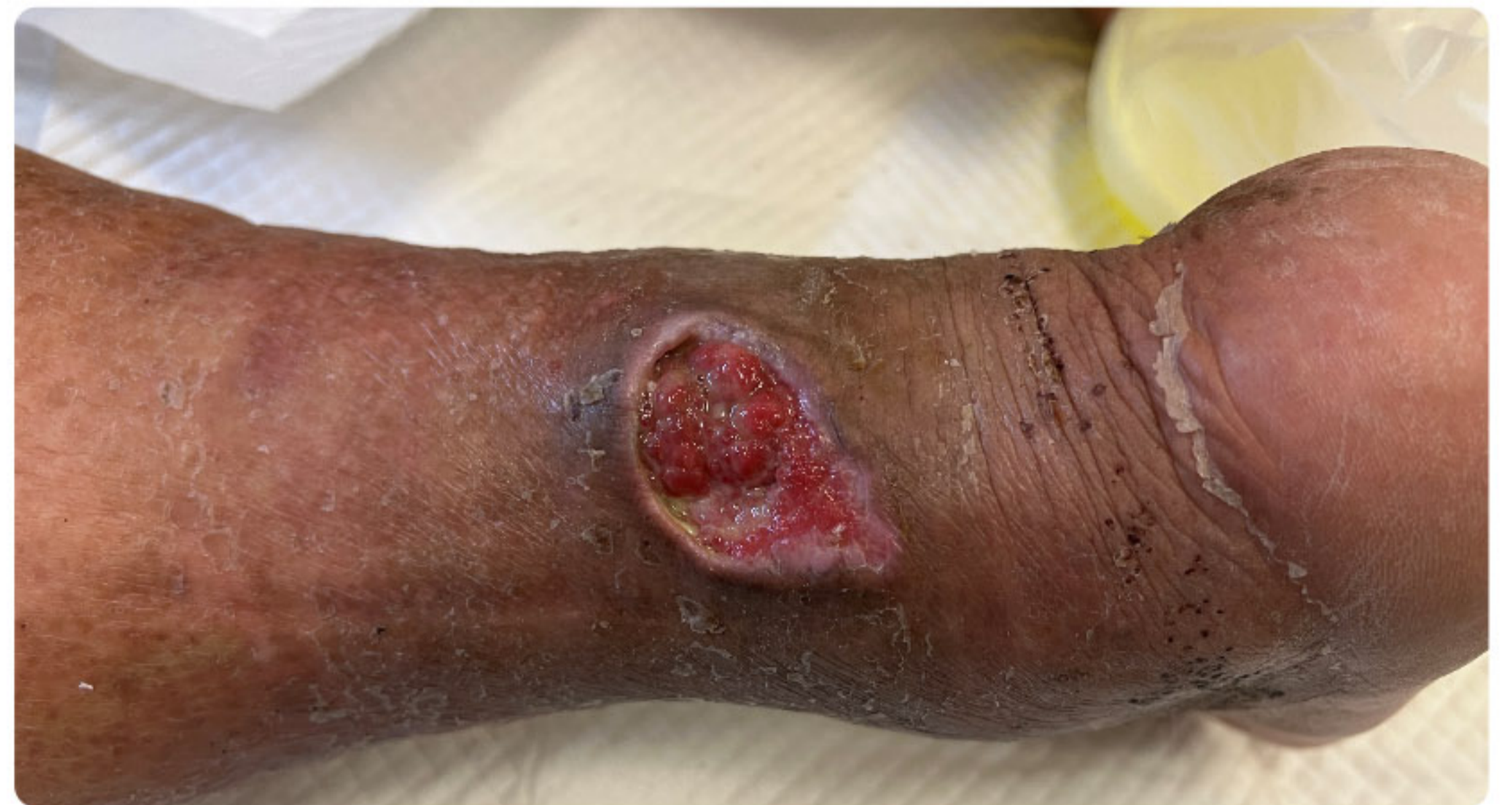During follow up silver alginate dressings were continued.

At 3 weeks post DEBRICHEM treatment the lesion showed good granulation (Figure C) and after 10 weeks post DEBRICHEM complete healing was observed (figure D).

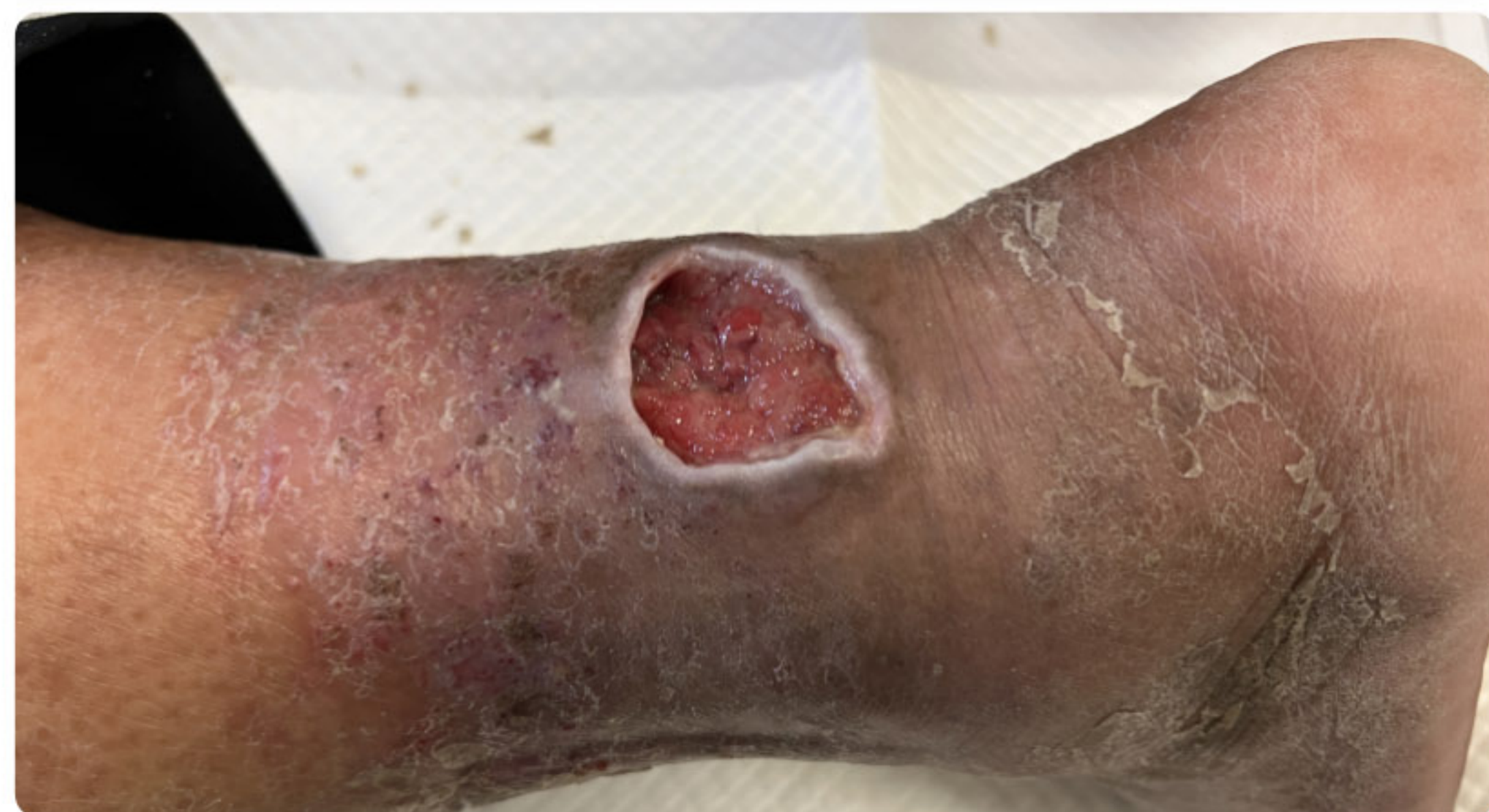PROGRESS



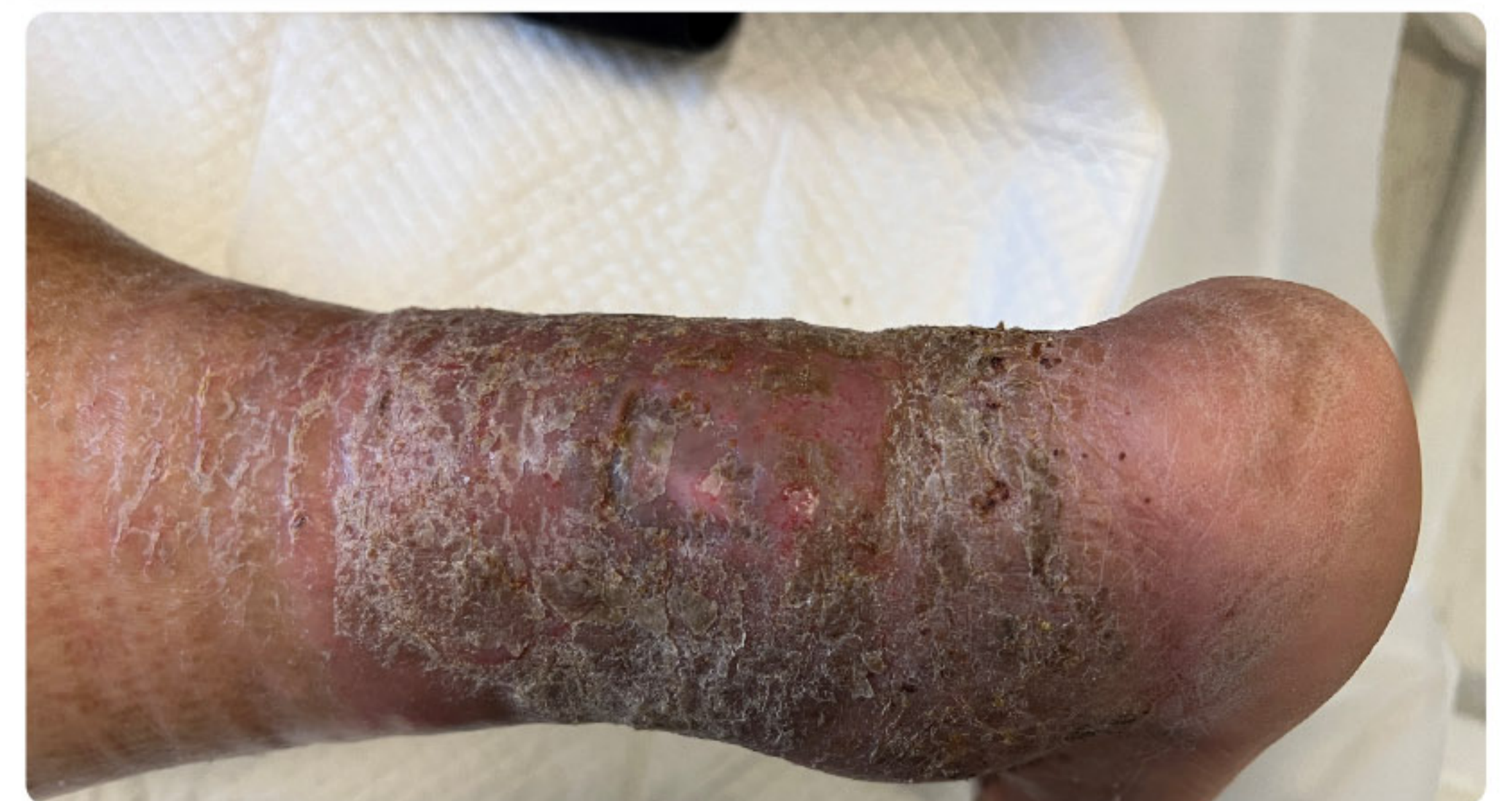1. Figure A: At presentation



2. Figure B: 2 weeks later at DEBRICHEM treatment



3. Figure C: 3 weeks post DEBRICHEM



4. Figure D: 10 weeks post DEBRICHEM

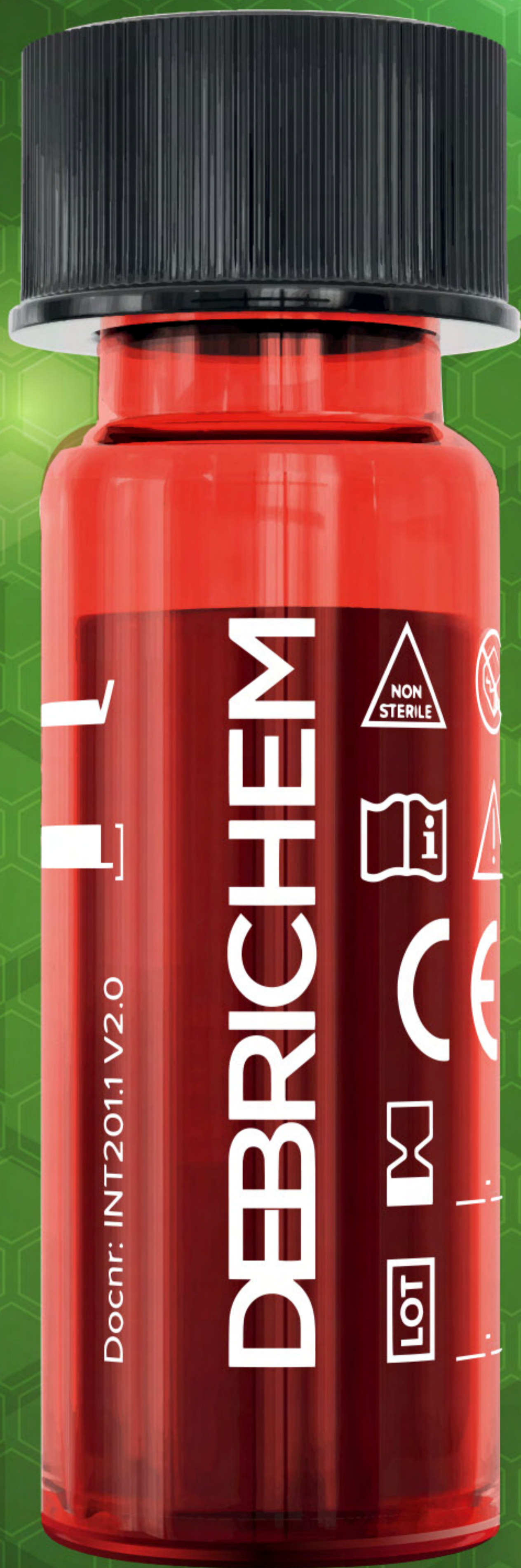

SCAN FOR MORE
DIGITAL MATERIALS

DEBRICHEM[®]

DEBRICHEM®

FUTURE OF WOUND CARE



PLAY VIDEO

